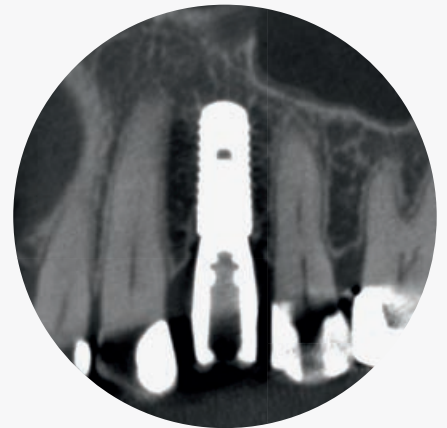
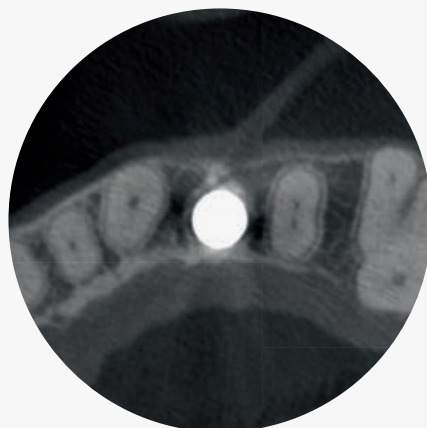
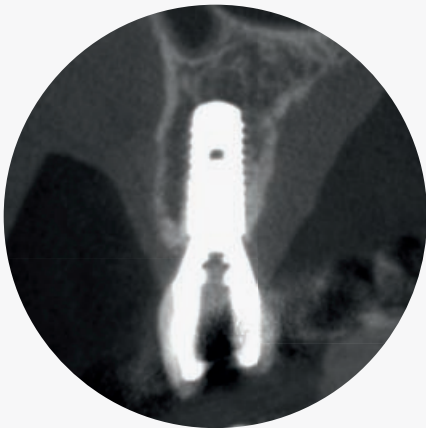# Implant Dentistry

The Use of Cone Beam Computed Tomography (CBCT)



# The Authors



**Prof. Dr. med. dent. Michael Bornstein**

Dental degree and thesis at the University of Basel. Board-certified oral surgeon since June 2003. In 2004, visiting assistant professor at the Department of Periodontics (Prof. Dr. D. Cochran) at the University of Texas Health Science Center at San Antonio, USA. Since autumn 2007 head Section of Dental Radiology and Stomatology at the Department of Oral Surgery and Stomatology at the University of Bern. In October 2009, Habilitation (Privatdozent / PD) in the field of „Oral Surgery and Stomatology“. Since 2014, Associate Professor at the University of Bern.

Fields of research: cone beam computed tomography (CBCT) in clinical dental practice, stomatology/oral medicine, GBR procedures with bioresorbable membranes and dental implants.



**Prof. Dr. med. dent. Daniel Buser**

Dr. Daniel Buser is Professor and Chairman at the Department of Oral Surgery at the University of Bern in Switzerland. He served as President of various academic associations including the European Association for Osseointegration (EAO) in 1996/97, the Swiss Society of Oral Implantology (SSOI) in 1999-2002, the Swiss Society of Oral Surgery and Stomatology (SSOS) in 2002-2007. Most recently, he was President of the ITI (2009-2013), the world's largest association in the field of implant dentistry. He received several scientific awards by professional organizations such as the ITI, the AO, the AAP and the AAOMS. Recently, he was honored with the Brånemark Osseointegration Award by the Osseointegration Foundation in the USA (2013).

His main research areas are in tissue regeneration around dental implants, surface technology and Guided Bone Regeneration. He has authored and co-authored more than 300 publications and several text books including two GBR books and two ITI Treatment Guides. He widely lectures at national and international conferences.

# Content

Preface	5
Technical details of the 3D Accuitomo 170	6
Dose optimization for CBCT imaging	8
CBCT imaging for implant treatment planning in the anterior maxilla	10
Case example: Replacement of a maxillary central incisor following dento-alveolar trauma	12
CBCT imaging for implant treatment planning in the posterior maxilla	14
Case example: Replacement of a missing first left maxillary molar following tooth loss due to endodontic complications	16
Case example: Replacement of missing maxillary premolars and molars in the posterior right maxilla (distal extension situation)	18
CBCT imaging for implant treatment planning in the posterior mandible	20
Case example: Extended edentulous space with two missing premolars in the posterior mandible	22
CBCT imaging for implant treatment planning in the anterior mandible	24
Case example: Replacement of missing mandibular incisors following bone loss due to periodontal disease	26
Examination of implant failures and complications using CBCT	28

1. Harris D, Horner K, Gröndahl K, Jacobs R, Helmrot E, Benic GI, Bornstein MM, Dawood A, Quirynen M: Guidelines for the use of diagnostic imaging in implant dentistry 2011: update of the E.A.O. A consensus workshop organized by the European Association for Osseointegration in the Medical University of Warsaw, Poland. *Clin Oral Implants Res* 2012;23:1243-53.

2. Mozzo P, Procacci C, Tacconi A, Tinazzi Martini P, Bergamo Andreis IA. A new volumetric CT machine for dental imaging based on the cone-beam technique: preliminary results. *Eur Radiol* 1998;8:1558-64.

3. De Vos W, Casselman J, Swennen GR. Cone-beam computerized tomography (CBCT) imaging of the oral and maxillofacial region: a systematic review of the literature. *Int J Oral Maxillofac Surg*. 2009;38:609-25.

4. Guerrero ME, Jacobs R, Loubele M, Schutyser F, Suetens P, van Steenberghe D. State-of-the-art on cone beam CT imaging for preoperative planning of implant placement. *Clin Oral Investig* 2006;10:1-7.

5. Bornstein MM, Al-Nawas B, Kuchler U, Tahmaseb A. Consensus statements and recommended clinical procedures regarding contemporary surgical and radiographic techniques in implant dentistry. *Int J Oral Maxillofac Implants* 2013; doi: 10.11607/jomi.2013.g1. (epub ahead of print).

# Preface

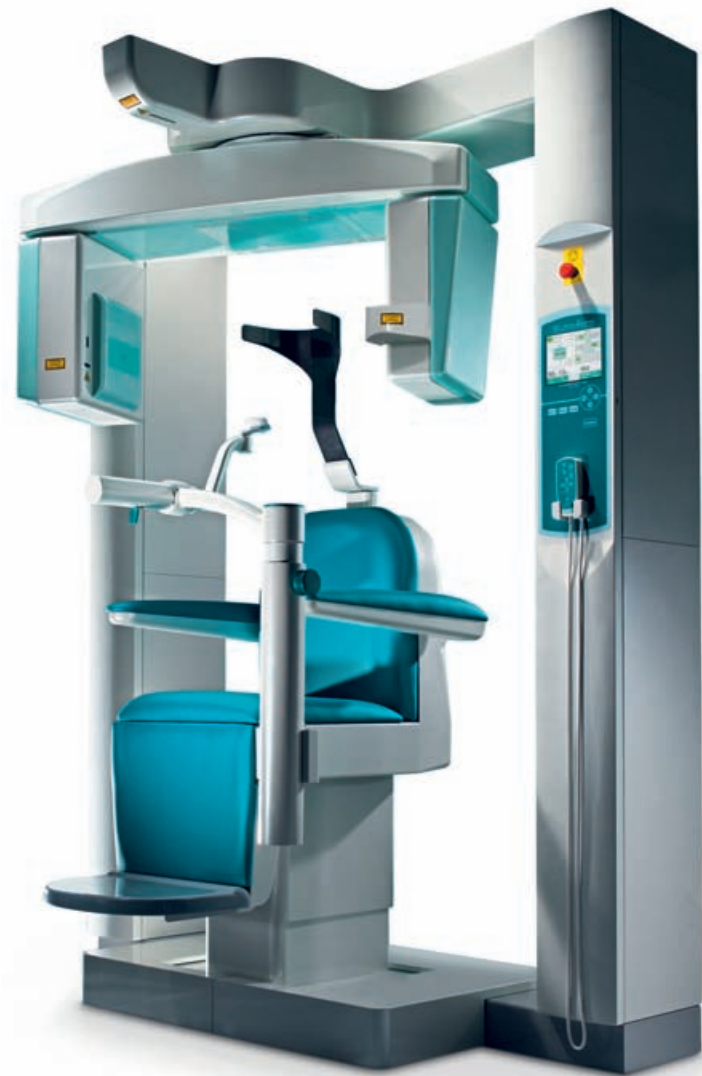Proper diagnosis and treatment planning in implant dentistry is done with a clinical examination and appropriate radiographs. For many years, the information required to satisfy these goals has been obtained from clinical examination and most commonly two-dimensional (2D) imaging such as intraoral periapical, lateral cephalometric and panoramic radiography. Using these imaging modalities, implants have been used predictably and with high success rates in clinical practice for more than 30 years. The decision to proceed to three-dimensional (3D) imaging should be based on clearly identified needs and the clinical and surgical requirements of the clinicians involved. Clinical situations that might benefit from 3D imaging prior to implant surgery are:<sup>1</sup>

1. When the clinical examination and conventional radiography have failed to adequately demonstrate relevant anatomical boundaries (e.g. nasopalatine fossa and canal, nasal fossa, mental foramen, submandibular gland fossa, inferior alveolar canal) and the absence of pathology such as retained root tips, sinus disease or adjacent inflammatory processes.
2. When reference to such images can provide additional information that can help to minimize the risk of damage to important anatomical structures.
3. In clinical borderline situations where there appears to be limited bone height and/or bone width available for successful implant treatment.
4. Where implant positioning can be improved. The diagnostic information can be enhanced by use of radiographic templates, computer assisted planning and surgical guides.

Since the first description in 1998,<sup>2</sup> cone beam computed tomography (CBCT) has become a popular and important technique for diagnosis and treatment planning in dental medicine.<sup>3</sup> It has already become an established diagnostic tool for various indications in dental medicine including dental implant surgery.<sup>4</sup> Today, when cross-sectional imaging is indicated for dental implant treatment planning purposes, CBCT is preferable over CT.<sup>5</sup>

The present brochure covers the different aspects of treatment planning for dental implants in the maxilla and mandible, presents the diagnosis of failures and complications, and discusses radiation dose protection issues with the use of CBCT imaging.

# Technical Details of the 3D Accuitomo 170



The 3D Accuitomo 170 is the 4th generation of the Accuitomo product line. It combines a high level of image quality with efforts to minimize patient dosage. The device offers different imaging modes, Fields of View (FOV) varying from small to large (maxillo-facial) FOVs, voxel sizes from 80  $\mu\text{m}$  to 250  $\mu\text{m}$ , zoom reconstructions to analyze areas of special interest with voxel sizes as small as 80  $\mu\text{m}$ , and a DICOM 3.0 compliant imaging software (i-Dixel 3D). Image acquisition with the 3D Accuitomo 170 is done by a rotating gantry composed of an X-ray source emitting a cone-shaped beam – in contrast to a fan-shaped beam

emitted by CT devices – and a detector that transmits the digital signals to the computer. The multiple projections (basis projection images) created during the rotation of the gantry are converted into secondary reconstructed 3-dimensional images that can be analyzed on a computer monitor. Cone beam computed tomography (CBCT) images are evaluated using the classical orthogonal planes (axial, sagittal and coronal), multiplanar reformation (MPR) to provide panorama-like thin-slice images and stacked sequential images orthogonal to the curved planar reformation, and 3D volume rendering.

Figure 1: The principle behind the CBCT technique, as its name implies, is a cone-shaped X-ray beam with the X-ray source and detector rotating around a point of interest in the patient. This figure shows a rotating gantry with x-ray source (so-called emitter) and detector attached to it.



Figure 2 (left): Orthogonal planes (axial, sagittal and coronal) in a patient referred for implant treatment planning.

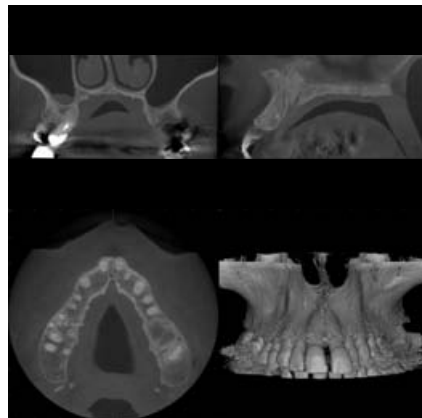


Figure 3 (right): 3D volume rendered jaw in a patient referred for dental implant treatment planning.

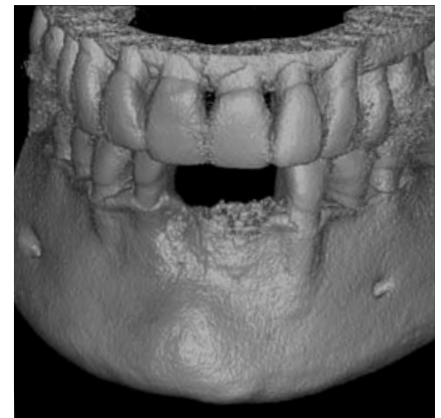
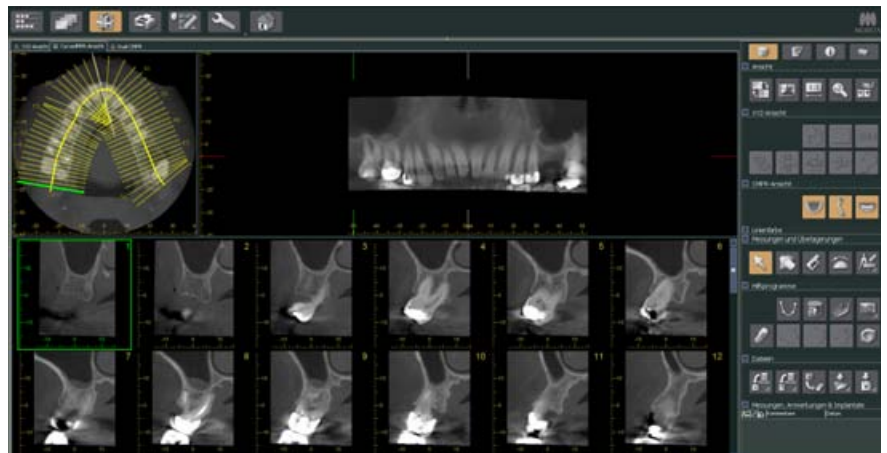


Figure 4: Multiplanar reformation (MPR) of the maxilla in a patient referred for dental implant treatment planning.



# Dose Optimization for CBCT Imaging

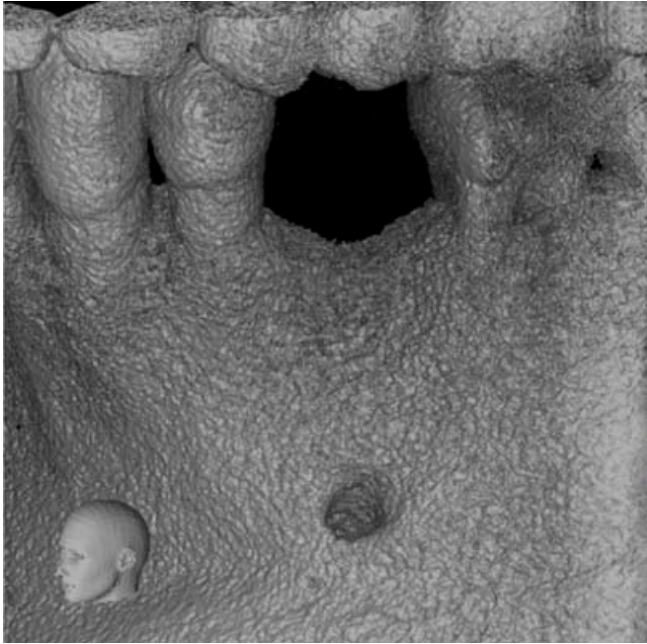


Figure 1: A small FOV (4 x 4 cm) of a single-tooth gap for evaluation and treatment planning prior to dental implant placement in area of the first left mandibular premolar.

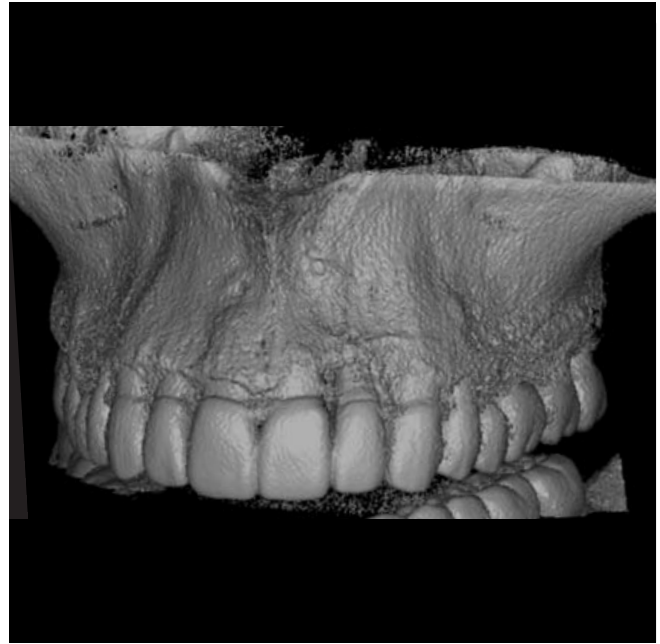


Figure 2: A medium FOV (8 x 4 cm) of the maxilla for evaluation of the peri-implant status of dental implants placed at the left lateral incisor and first molar regions.

Patient risk from radiation has been a continuing concern in oral and maxillofacial imaging, due to the frequency of X-ray examinations in dental practice. ALARA is the acronym for As Low As Reasonably Achievable and is a fundamental principle for diagnostic radiology.<sup>1</sup> With the increased use of CBCT imaging in dental practice, clinicians must be made aware that patient radiation doses associated with CBCT imaging are higher than those of conventional radiographic techniques. Therefore, routine replacement of current radiographic techniques must be considered with great care – especially when treating children. Strategies which optimize exposure, such as Field of View (FOV) reduction to the region of interest, and reduction in exposure parameters often provide images of sufficient image quality for most diagnostic tasks associated with dental procedures.

**For the 3D Accuitomo 170 the following FOVs are available (as classified by Bornstein et al. 2013):<sup>2</sup>**

Small FOV

< 40 cm<sup>2</sup> / diameter x height in cm; Figure 1:  
4 x 4 cm; 6 x 6 cm  
6 x 4 cm (optional); 6 x 5 cm (optional)

Medium / dento-alveolar FOV

40 cm<sup>2</sup> to < 100 cm<sup>2</sup>; Figure 2 and 3:  
8 x 8 cm; 10 x 5 cm; 14 x 5 cm; 17 x 5 cm  
8 x 4 cm (optional); 8 x 5 cm (optional)

Large / maxillo-facial FOV

> 100 cm<sup>2</sup>; Figure 4:  
10 x 10 cm; 14 x 10 cm; 17 x 12 cm



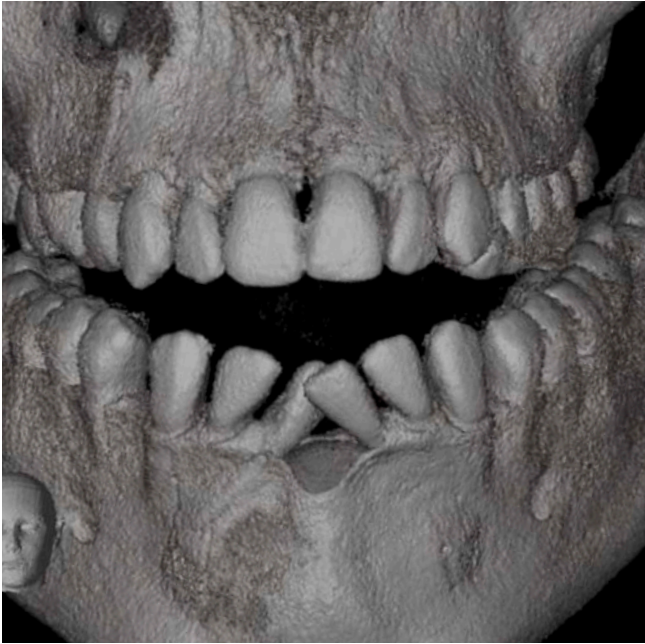

Figure 3: A medium FOV (8 x 8 cm) in a patient referred for diagnosis of multiple cystic lesions in the upper and lower jaw.

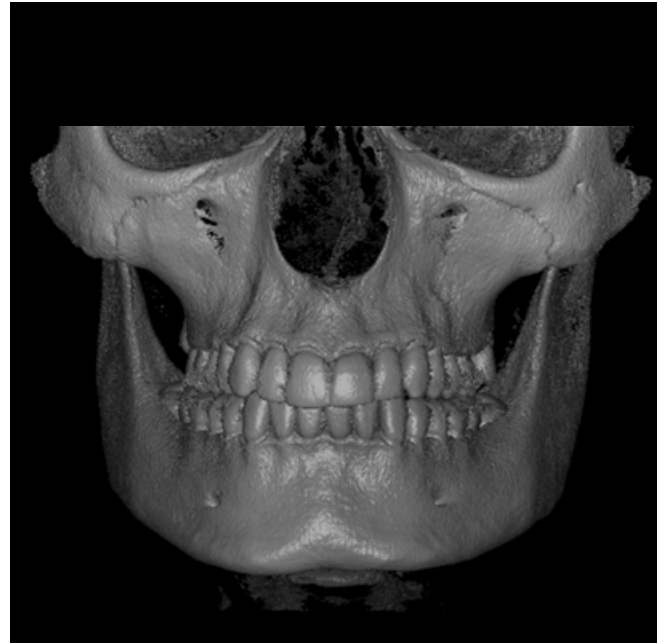

Figure 4: A large FOV (14 x 10 cm) has been used for the evaluation of all maxillary and mandibular third molars and the TMJ regions.

**Additionally, four imaging modes are available to select the appropriate scan time, while keeping patient dose to a minimum:**

Standard mode (360°: 17.5 seconds / 180°: 9.0 seconds): This is the standard setting used for most patients and FOVs. Most of the studies published using the Accuitomo device have applied this mode.

High resolution mode (360°: 30.8 seconds / 180°: 15.8 seconds): This setting is used for detailed bone or tooth structures within small FOVs. Usually indicated for adults, not children.

High fidelity mode (360°: 30.8 seconds / 180°: 15.8 seconds): Used for zoom reconstructions, and indicated for adults, not children.

High speed mode (360°: 10.5 seconds / 180°: 5.4 seconds): Used to reduce motion artefacts, especially for children and small FOVs.

1. Farman AG: ALARA still applies Oral Surg Oral Med Oral Pathol Oral Radiol Endod 2005;100:395-7.

2. Bornstein MM, Scarfe WC, Vaughn VM, Jacobs R: Cone beam computed tomography in implant dentistry: a systematic review focusing on guidelines, indications, and radiation dose risks. Int J Oral Maxillofac Implants 2014 (in press).

# CBCT Imaging for Implant Treatment Planning in the Anterior Maxilla

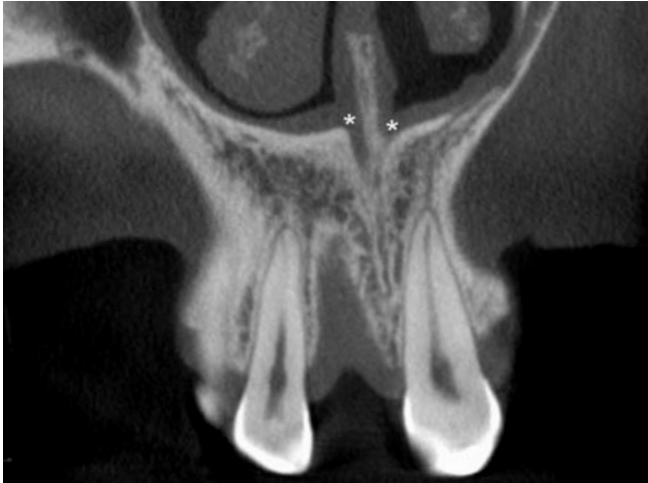

Figure 1A: Coronal CBCT slice through the alveolar socket of the missing right central incisor and the neighboring teeth. (\*) Nasal openings (foramina of Stenson) of the nasopalatine canal

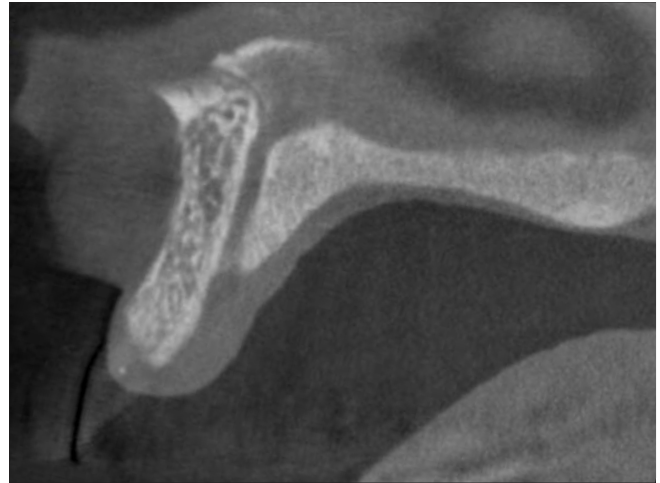


Figure 1B: Sagittal CBCT slice

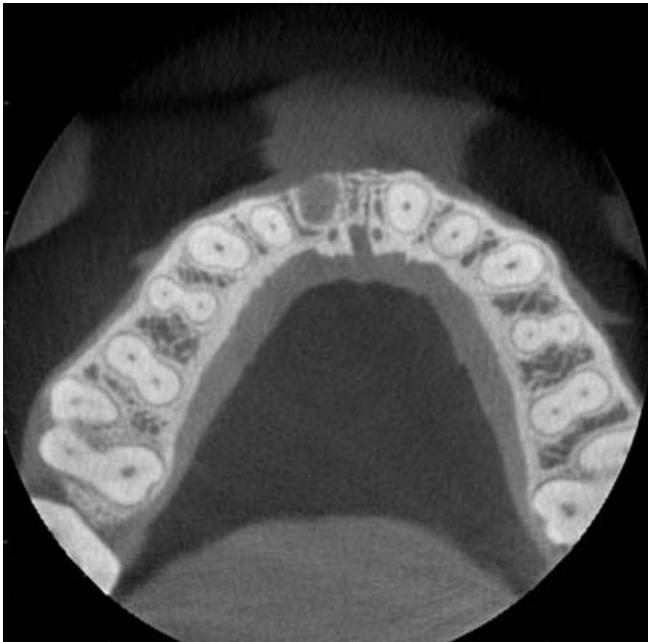

Figure 1C: Axial CBCT slice

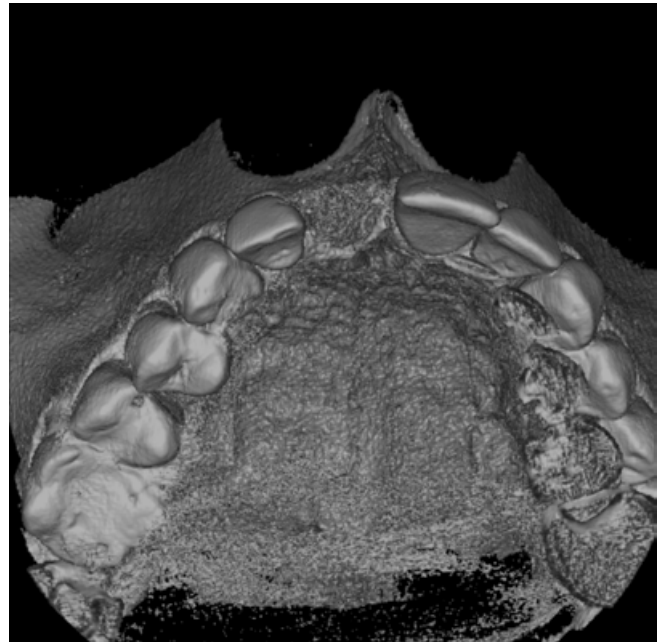


Figure 1D: Volume rendered data set

Figure 1: Visualization of the nasopalatine canal in a patient referred for dental implant treatment planning in the anterior maxilla (right central incisor). The canal consists of two parallel bony channels.

## Relevant clinical questions

Is a correct 3-dimensional (3D) implant positioning possible?  
Besides reestablishing function, the esthetic result of the implant rehabilitation is of great importance in the anterior maxilla. Therefore, the clinician needs to achieve a correct oro-facial, mesio-distal, and corono-apical position of the prospective implant shoulder.

Can we achieve good primary stability of the implant in the desired position? If primary stability of an inserted dental implant is not achievable, the clinician has to decide between site development using guided bone regeneration (GBR) or an alternative treatment concept without dental implants.

When GBR is needed, can we use a simultaneous approach with implant insertion or do we need a staged approach?

When GBR is not indicated, can we place the implant using a flapless approach?

## Anatomic structures of interest

Anatomical structures and boundaries that need to be considered, when planning a dental implant in the anterior maxilla include:

Nasal floor

Nasopalatine canal (Figure 1)<sup>1</sup>

Anterior superior alveolar canal and canalis sinuosus (Figure 2)

1. Bornstein MM, Balsiger R, Sendi P, von Arx T: Morphology of the nasopalatine canal and dental implant surgery: A radiographic analysis of 100 consecutive patients using limited cone beam computed tomography. Clin Oral Implants Res 2011;22:295-301.

Figure 2: Patient referred for dental implant treatment planning exhibiting a visible canalis sinuosus (+) on the left in the coronal CBCT slice. From the canalis sinuosus, an anterior maxillary canal (\*) runs to the anterior palate in the vicinity of the canine.

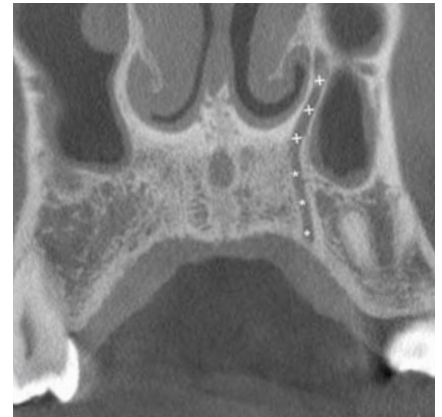


Figure 2A: Coronal CBCT slice

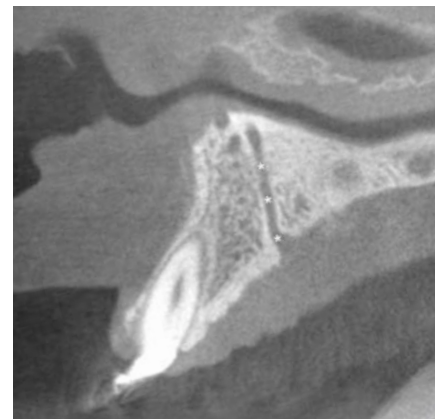


Figure 2B: Sagittal CBCT image

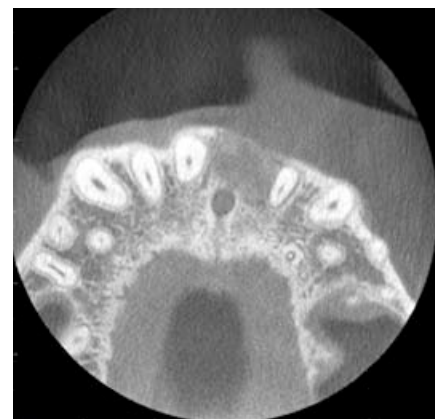

Figure 2C: Axial CBCT image

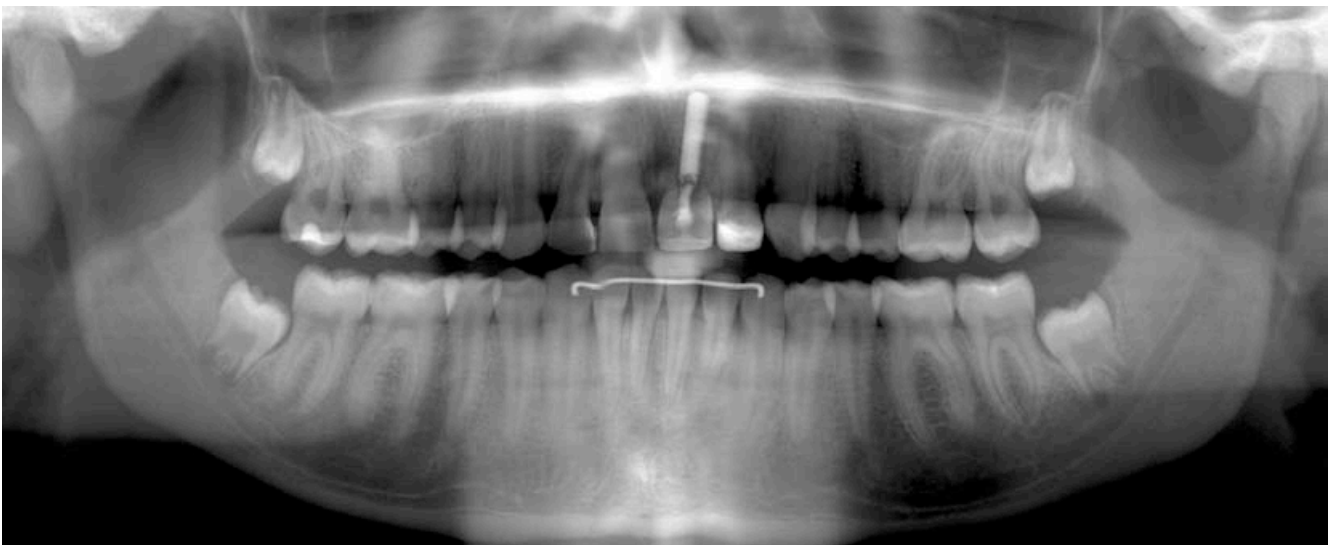
# Case Example

Replacement of a maxillary central incisor following dento-alveolar trauma

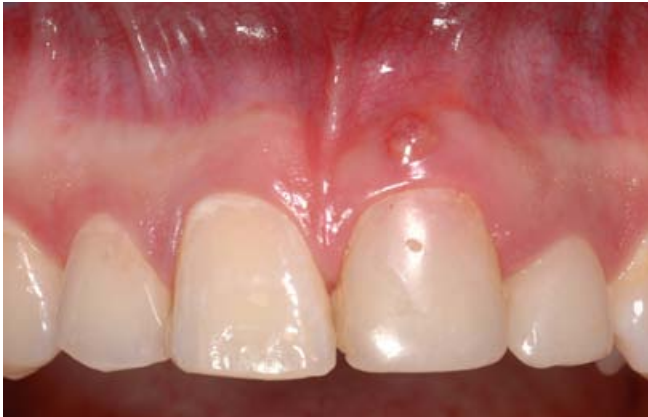

Figure 1: Initial clinical presentation of a 19-year old female patient referred for dental implant treatment planning. The patient had an avulsion of the maxillary left central incisor with 8 years. The tooth was replanted using a titanium post. Since a few months, the patient had noticed a buccal fistula and growing „pinkish“ discoloration of the tooth.

Figure 2: Panoramic view of the patient exhibiting the replanted maxillary left central incisor. A lytic, hypodense region is visible between the crown of the respective tooth and the titanium post. The root of the central incisor is not discernible – and seems to have been resorbed in most parts. Additional findings include non-erupted third molars in the maxilla and mandible.



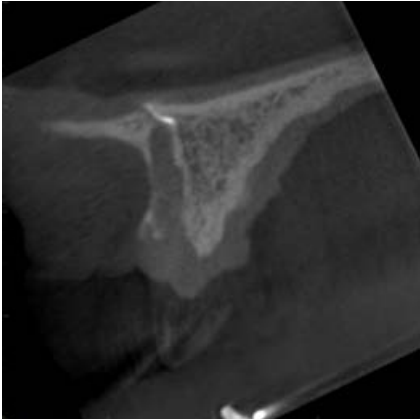


Figure 3A: Sagittal CBCT image

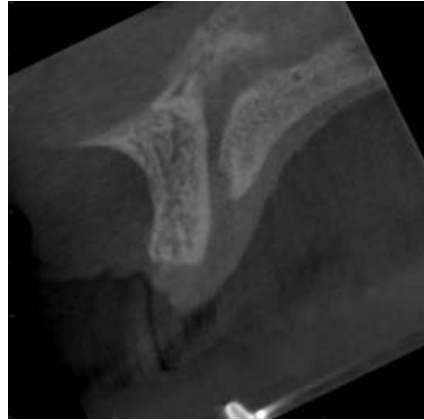

Figure 3B: Sagittal CBCT image

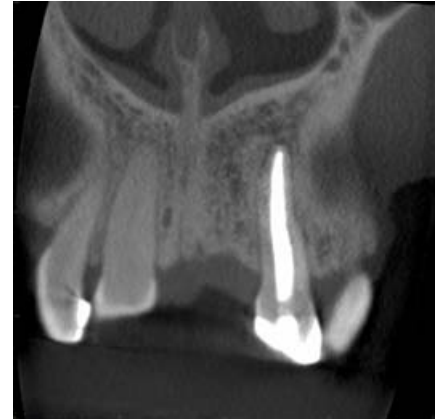

Figure 3C: Coronal CBCT image

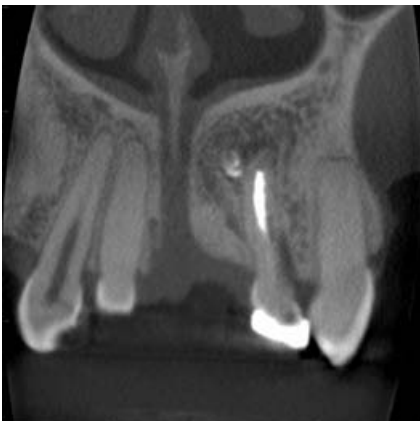

Figure 3D: Coronal CBCT image

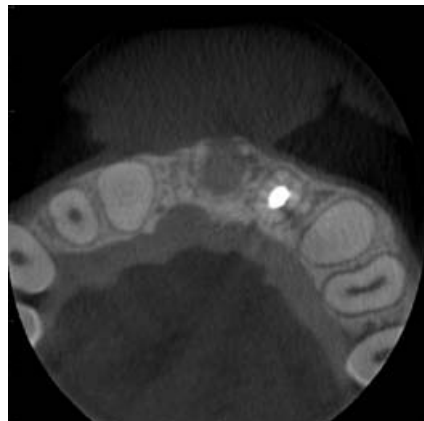

Figure 3E: Axial CBCT image

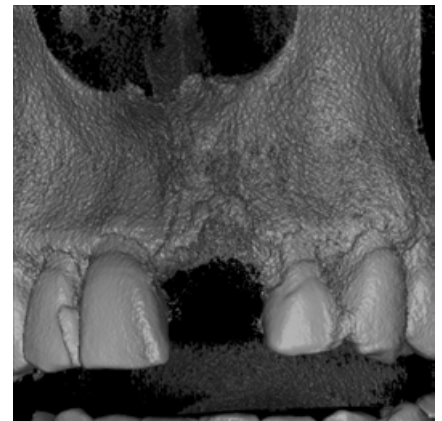

Figure 3F: Volume rendered data set

Figure 3: CBCT analysis of the site after extraction of the left maxillary central incisor including the titanium post (small FOV: 4 x 4 cm): the evaluation of the images exhibits a root canal filled left lateral incisor, a prominent nasopalatine canal (Y-shaped), and visible excessive root canal filling material in the bone apically to both maxillary left incisors.

Based on the findings of the CBCT images, a dental implant placement with simultaneous guided bone regeneration was planned.

Figure 4: Radiographic (A) and clinical (B) presentation two years after dental implant insertion in the region of the left maxillary central incisor.

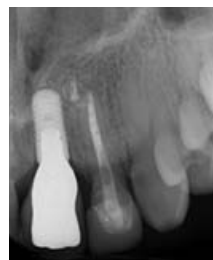

Figure 4A

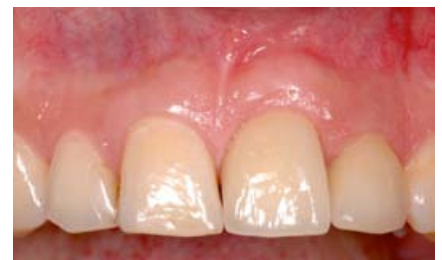

Figure 4B

# CBCT Imaging for Implant Treatment Planning in the Posterior Maxilla

## Relevant clinical questions

Is correct 3-dimensional (3D) implant positioning possible?

Can we achieve good primary stability of the implant in the desired position? If primary stability of an inserted dental implant is not achievable, the clinician has to decide between site development using sinus floor elevation (SFE) procedures or an alternative treatment concept not using dental implants.

When SFE is needed, can we use a simultaneous SFE with implant insertion or do we need a staged approach?

When a simultaneous SFE is possible, do we use a lateral window or a transcrestal osteotome technique?

## Anatomic structures of interest

It has been established that panoramic views of the posterior maxilla will underestimate the amount of bone available for implant placement. CBCT can overcome this problem as it provides more accurate measurements of the available bone volume. CBCT can also provide information on arterial channels in the lateral wall of the sinus, the presence, and extent of any septae, as well as on the health of the sinus such as absence of sinus membrane thickening, polyps or fluid levels.<sup>1</sup>

Anatomical structures and boundaries that need to be considered, when planning a dental implant in the posterior maxilla include:

Maxillary sinus and related structures: this includes the extension (pneumatization) of the sinus, the status of the Schneiderian membrane (dimension and type of thickening), presence of bony septa, opacification of the maxillary sinus (sinusitis or mucocele). The sinus mucosa exhibits various morphological alterations:<sup>2</sup> healthy Schneiderian membrane (no thickening, Figure 1); flat and shallow thickening (Figure 2); semi-aspherical thickening rising in an angle of > 30° from the floor of the walls of the sinus; mucocele-like / complete opacification of the sinus (Figure 3); mixed flat and semi-aspherical thickenings.

Posterior superior alveolar canal

Maxillary tuberosity

Pterygoid plates

1. Harris D, Horner K, Gröndahl K, Jacobs R, Helmrot E, Benic GI, Bornstein MM, Dawood A, Quirynen M: E.A.O. Guidelines for the use of diagnostic imaging in implant dentistry 2011. A consensus workshop organized by the European Association for Osseointegration at the Medical University of Warsaw. Clin Oral Implants Res 2012;23:1243-53.

2. Janner SFM, Caversaccio M, Dubach P, Sendi P, Buser D, Bornstein MM: Characteristics and dimensions of the Schneiderian membrane: A radiographic analysis using cone beam computed tomography in patients referred for dental implant surgery in the posterior maxilla. Clin Oral Implants Res 2011;22:1446-53.

Figure 1: Visualization of the right posterior edentulous maxilla and maxillary sinus in a patient referred for dental implant treatment planning. The maxillary sinus is pneumatized without any signs of a thickening of the Schneiderian membrane.

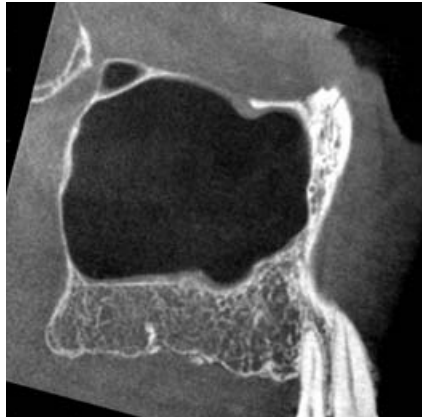


Figure 1A: Sagittal CBCT slice

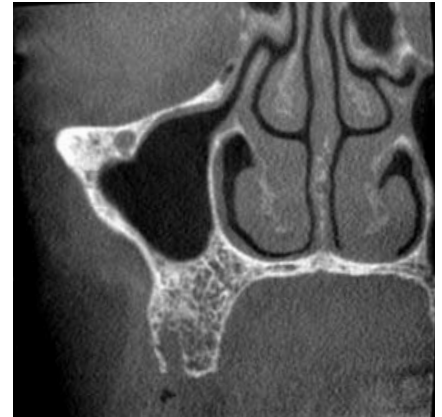


Figure 1B: Coronal CBCT slice

Figure 2: Patient referred for dental implant treatment planning in the posterior maxilla exhibiting a flat, shallow thickening of the Schneiderian membrane.

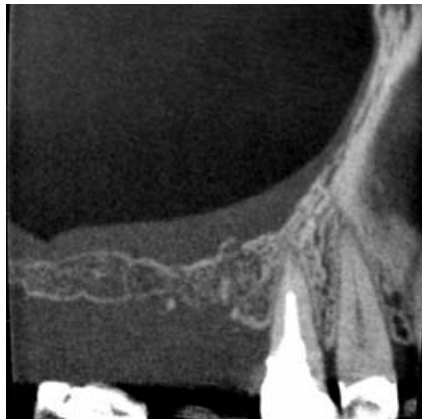

Figure 2A: Sagittal CBCT image

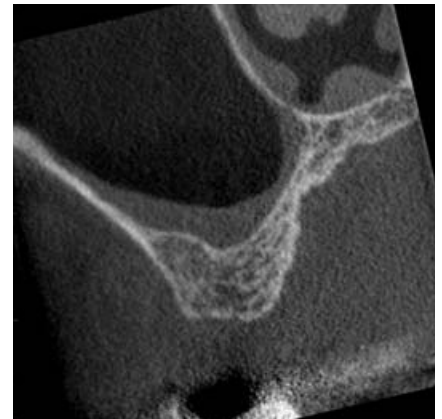


Figure 2B: Axial CBCT image

Figure 3: Patient exhibiting an almost complete opacification of the maxillary sinus and a bony septum in the region between the second and third molar extending from the buccal to the palatal. The first molar exhibits an apical radiolucency, and the alterations in the maxillary sinus can be diagnosed as a sinusitis of odontogenic origin.

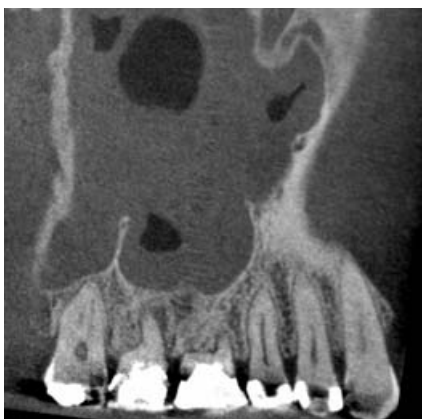

Figure 3A: Sagittal CBCT image

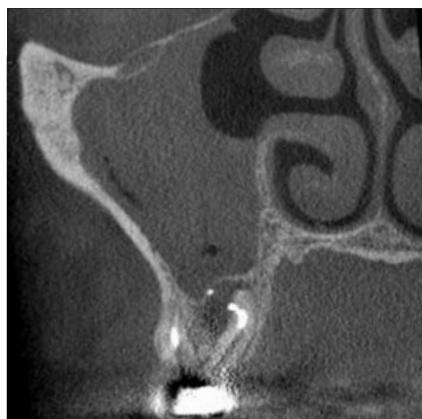


Figure 3B: Coronal CBCT image

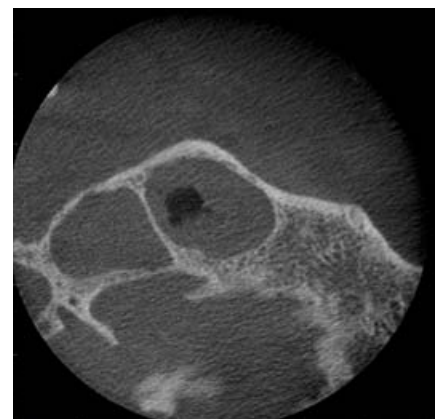


Figure 3C: Axial CBCT image

# Case Example

Replacement of a missing first left maxillary molar following tooth loss due to endodontic complications

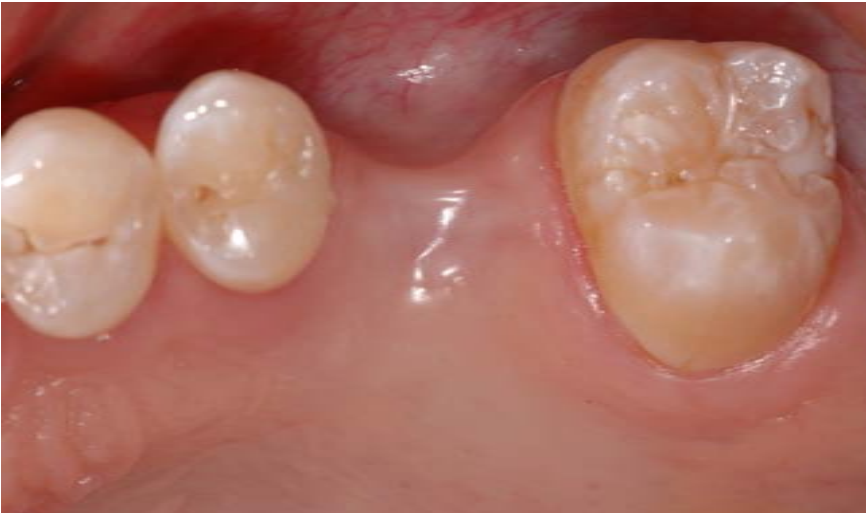

Figure 1: Initial clinical presentation of a 41-year old male patient referred for dental implant treatment planning. The patient had an extraction of the first left maxillary molar following a failed root canal treatment one year ago.

Figure 2: Panoramic view of the patient exhibiting the single-tooth gap in the upper left posterior maxilla. Additional findings include agenesis of both lateral maxillary incisors. Otherwise, there are no pathologic findings in the radiograph.

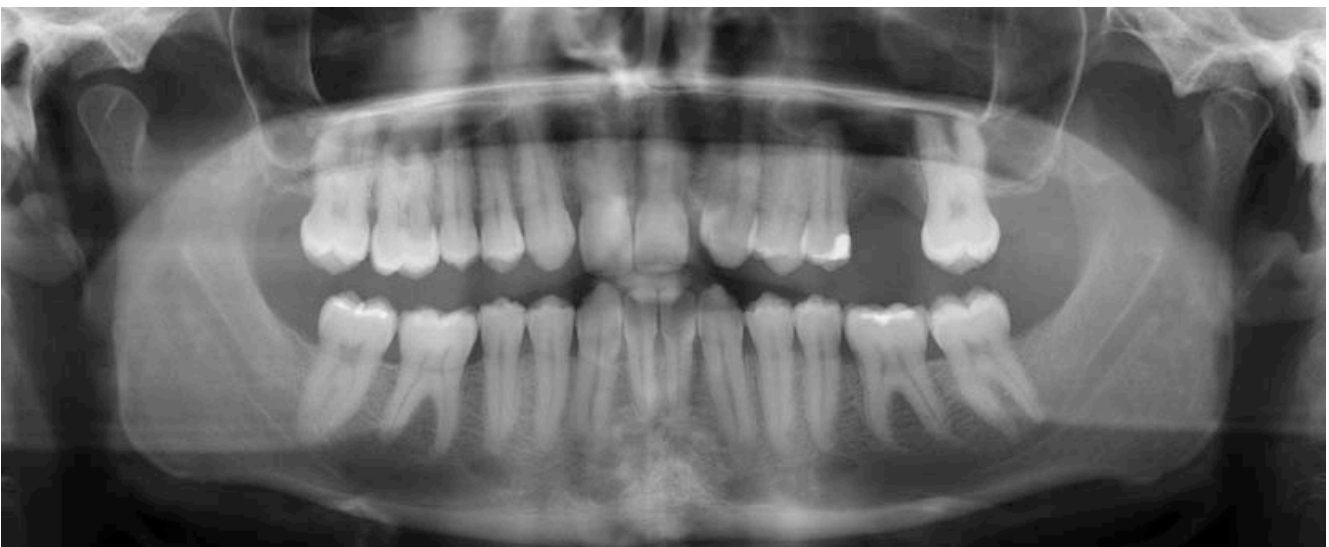



Figure 3: CBCT analysis of the left posterior maxilla including the missing first molar area (small FOV: 6 x 5 cm): the evaluation of the images exhibits well pneumatized maxillary sinus without any pathologic findings, premolars and a second molar without fillings or other signs of decay, and a reduced vertical bone height and even missing bone towards the maxillary sinus in the region of the first molar.

Figure 3D: The coronal slice exhibits an enamel pearl in the furcation area of the second molar (\*).

Based on these findings, a staged sinus floor elevation procedure with implant insertion was planned and discussed with the patient.

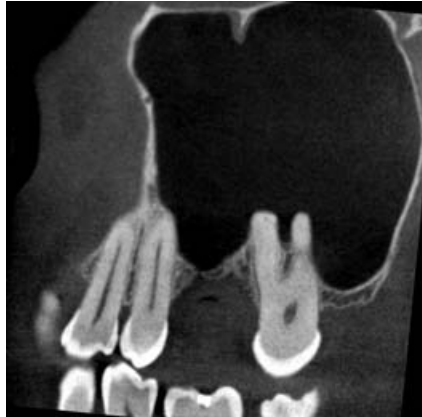

Figure 3A: Sagittal CBCT image

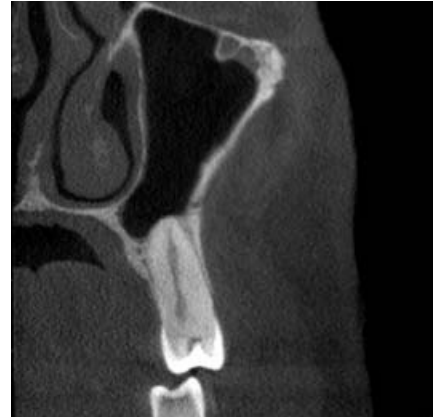

Figure 3B: Coronal CBCT image

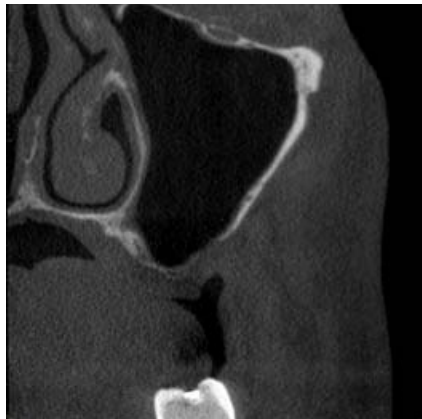

Figure 3C: Coronal CBCT image

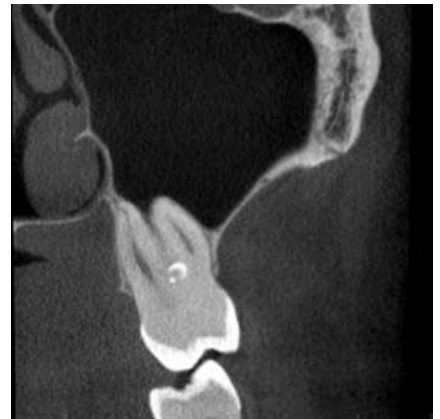

Figure 3D: Coronal CBCT image

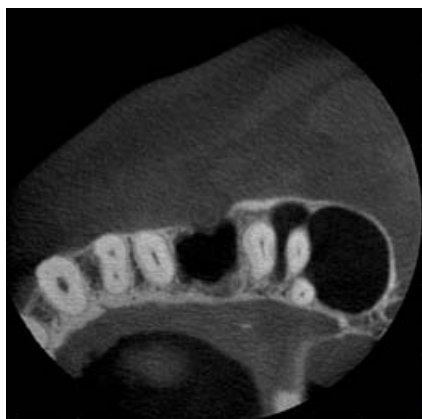

Figure 3E: Axial CBCT image

# Case Example

Replacement of missing maxillary premolars and molars in the posterior right maxilla (distal extension situation)

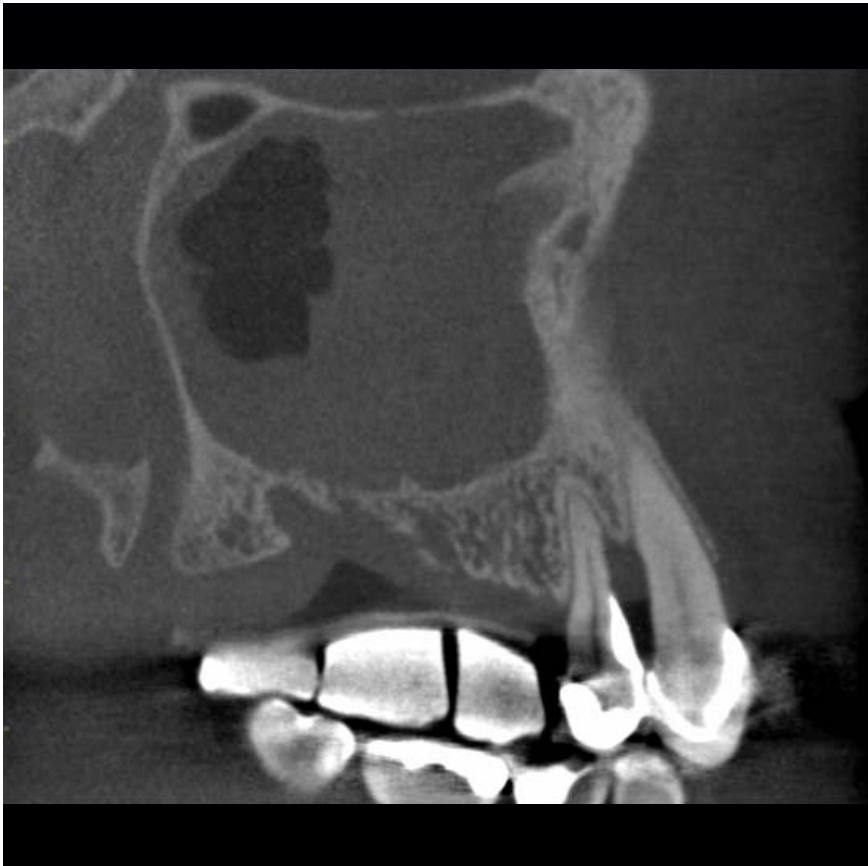


Figure 1A: Sagittal CBCT image

Figure 1: A 73-year old male patient was referred for dental implant treatment planning in the right posterior maxilla. Upon initial examination he did not report any acute medical problems. He had lost the molars and the second premolar due to periodontal and endodontic complications. CBCT analysis of the right posterior maxilla using a radiographic template (small FOV: 6 x 5 cm) exhibits reduced vertical bone height in the molar area, bone loss between the canine and the first premolar, and opacification of the right maxillary sinus.

The tentative diagnosis was a maxillary sinusitis of rhinogenic origin. Based on these findings, the patient was referred to the ear, nose, throat (ENT) specialist for further diagnosis and treatment.

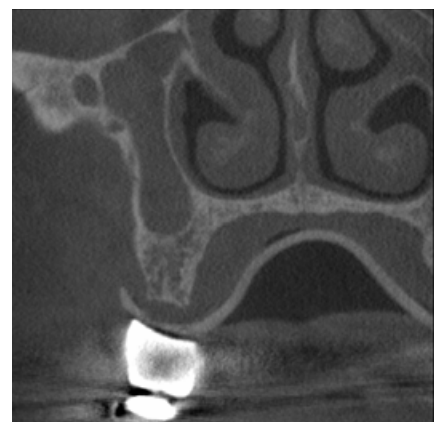


Figure 1B: Coronal CBCT image, second premolar region

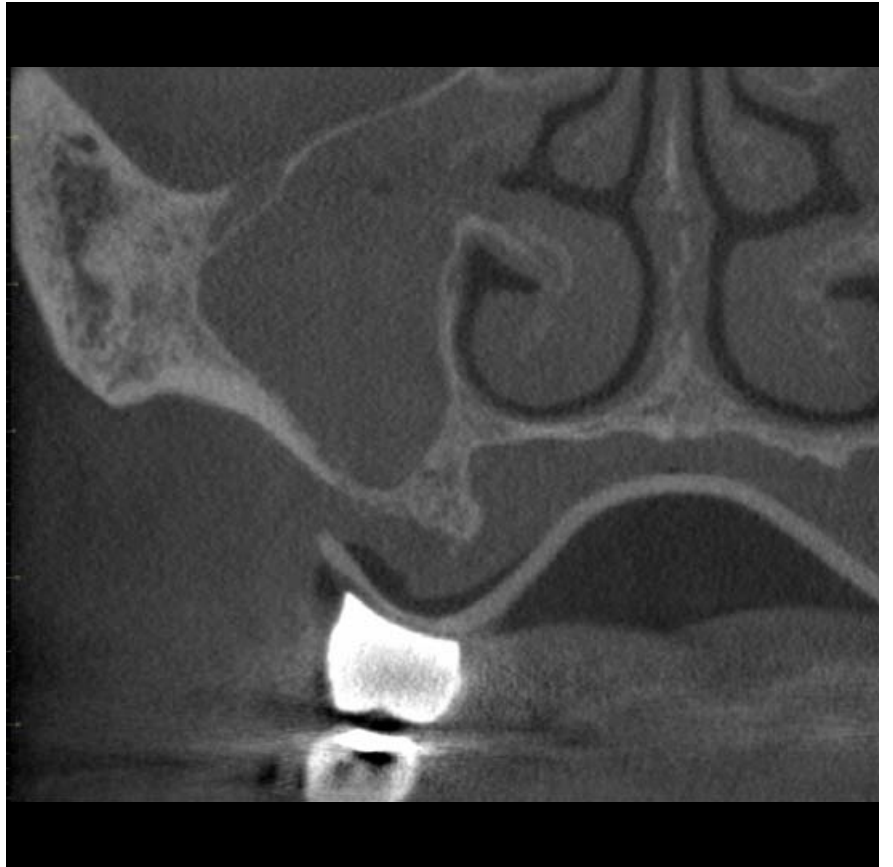

Figure 1C: Coronal CBCT image, first molar region

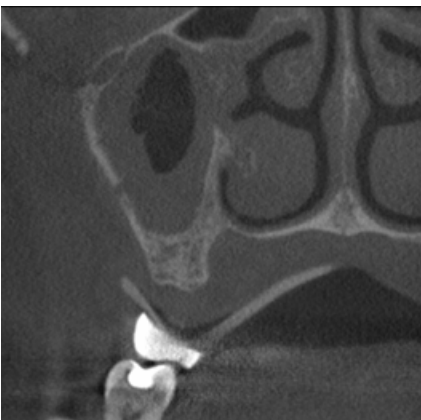


Figure 1D: Coronal CBCT image, second molar region

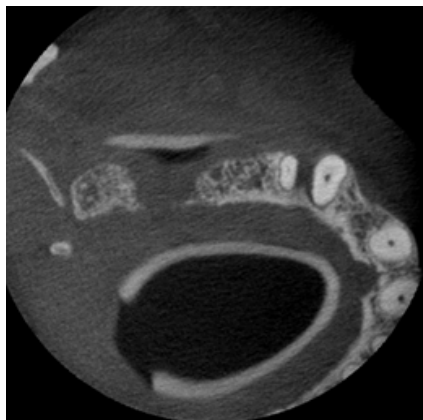

Figure 1E: Axial CBCT image, bone loss between canine and first premolar is visible

# CBCT Imaging for Implant Treatment Planning in the Posterior Mandible

## Relevant clinical questions

Is correct 3-dimensional (3D) implant positioning possible? This includes the number and dimensions (length and diameter) of the implants to be inserted?

Can we achieve good primary stability of the implant in the desired position? If primary stability of the implant is not achievable, the clinician has to decide between site development using guided bone regeneration (GBR) or an alternative treatment concept without dental implants.

When GBR is needed, can we use a simultaneous approach with implant insertion or do we need a staged procedure?

When GBR is not indicated, can we place the implant using a flapless approach?

## Anatomic structures of interest

Anatomical structures and characteristics of the posterior mandible that need to be considered, when planning dental implant insertion are:

Inferior alveolar nerve canal / mandibular canal (Figures 1 and 2): The intraosseous course of the inferior alveolar nerve is not always straightforward. Thus the risk for a surgical injury may vary accordingly. A bifid mandibular canal has been reported with a frequency of 1%.<sup>1</sup>

Mental foramina (Figure 1)

Retromolar foramen<sup>2</sup>

Sublingual fossa („lingual undercut“; Figure 2): Perforation of the lingual cortical plate during implant placement in the posterior mandible can be a severe surgical complication and the presence of a lingual undercut is considered an important anatomical risk factor.<sup>3</sup>

1. de Oliveira-Santos C, Souza PH, de Azambuja Berti-Couto S, Stinkens L, Moyaert K, Rubira-Bullen IR, Jacobs R: Assessment of variations of the mandibular canal through cone beam computed tomography. Clin Oral Investig 2012;16:387-93.

2. von Arx T, Hänni A, Sendi P, Buser D, Bornstein MM: Radiographic study of the mandibular retromolar canal: an anatomic structure with clinical importance. J Endod 2011;37:1630-35.

3. Braut V, Bornstein MM, Lauber R, Buser D: Bone dimensions in the posterior mandible – a retrospective radiographic study using cone beam computed tomography. Part 1 - Analysis of dentate sites. Int J Perio Rest Dent 2012;32:175-84.

Figure 1: Visualization of the course of the mandibular canal (+) in a patient referred for dental implant treatment planning in the right posterior mandible (first molar region). The mental foramen (\*) can be seen apically to the second premolar.

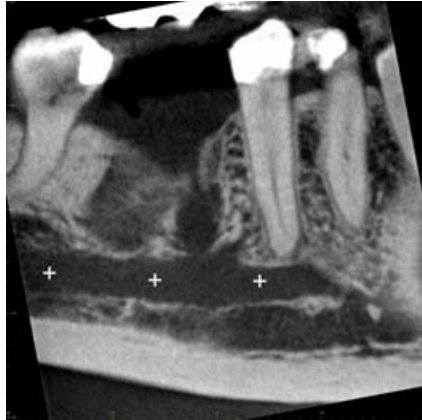

Figure 1A: Sagittal CBCT slice

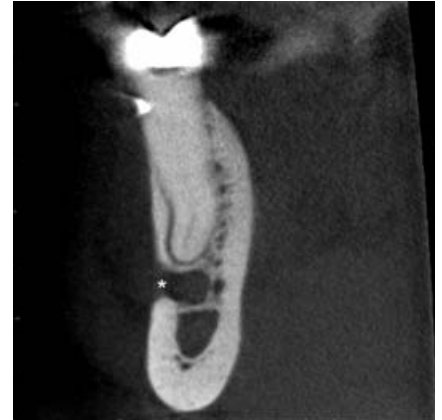

Figure 1B: Coronal CBCT slice

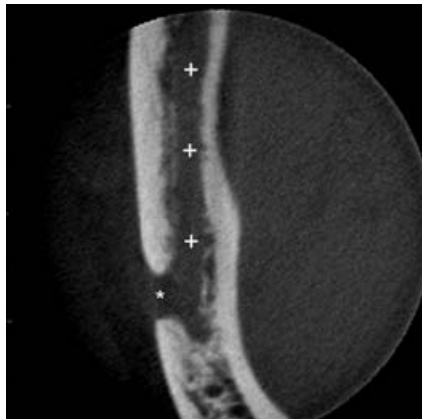

Figure 1C: Axial CBCT slice

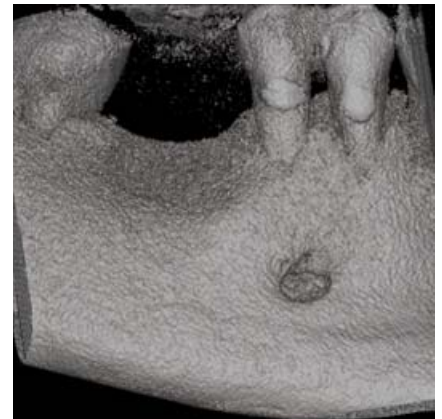

Figure 1D: Volume rendered data set

Figure 2: Patient referred for dental implant treatment planning in the left posterior mandible (first molar) exhibiting a distinct lingual undercut. + = mandibular canal; \* = lingual undercut.

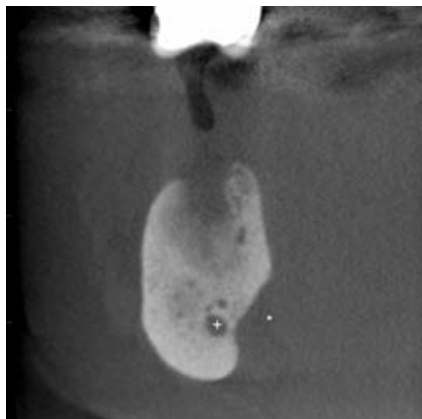


Figure 2A: Coronal CBCT image

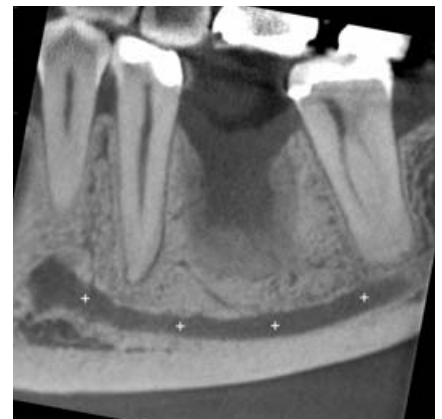

Figure 2B: Sagittal CBCT image

# Case Example

Extended edentulous space with two missing premolars in the posterior mandible

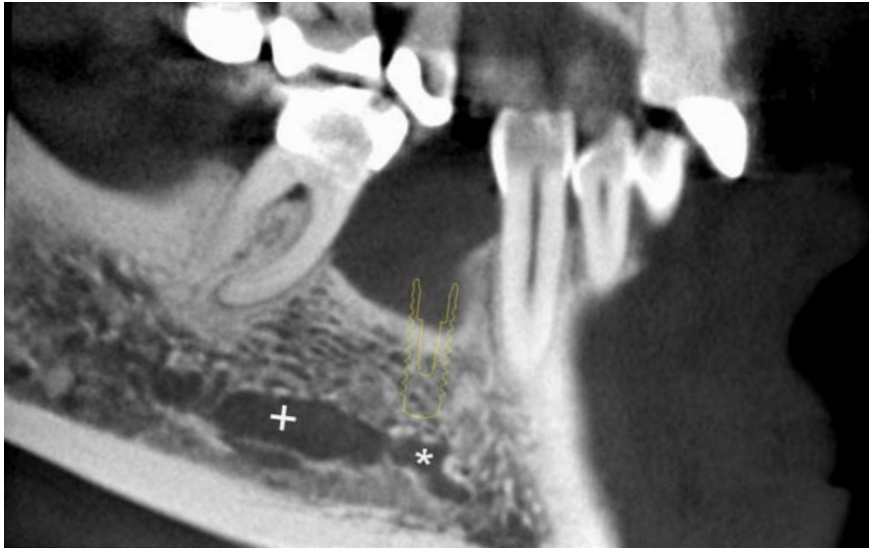


Figure 1A: Sagittal CBCT image with mandibular (+) and incisive canal (\*)

Figure 1: CBCT analysis of a patient referred for dental implant treatment planning of an extended edentulous space in the posterior mandible with two missing premolars. Due to the reduced vertical and horizontal dimensions of the alveolar ridge and the location of the mental foramen, safe dental implant insertion is only possible in the region of the first premolar. The desired future position and angulation of the implant can be evaluated in three dimensions demonstrating the need for simultaneous guided bone regeneration procedures at the crestal region and the distances to the mental foramen and incisive canal.

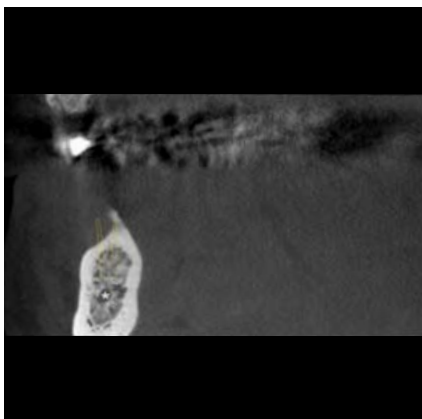


Figure 1B: Coronal CBCT image with incisive canal (\*)

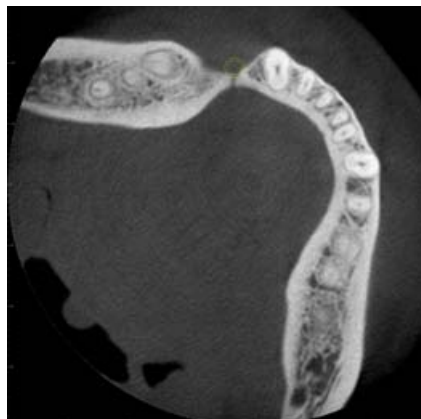


Figure 1C: Axial CBCT image

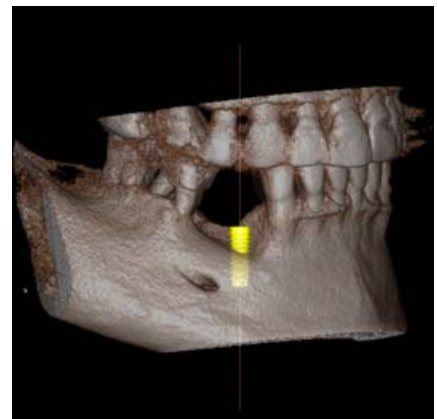


Figure 1D: Volume rendered data set

Figure 2: CBCT analysis further reveals furcation involvement of the first molar (Figures A to C) and a root remnant of the first premolar located distally to the apex of the canine (Figures D to F).

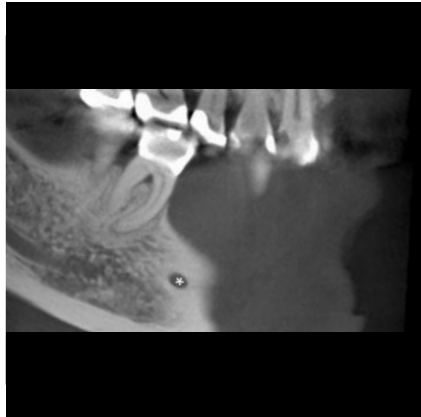


Figure 2A: Sagittal CBCT image with mental foramen (\*)

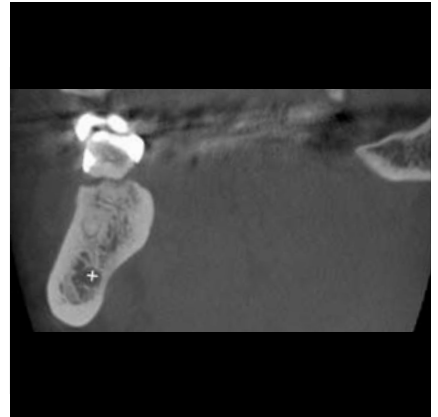


Figure 2B: Coronal CBCT image with mandibular canal (\*)

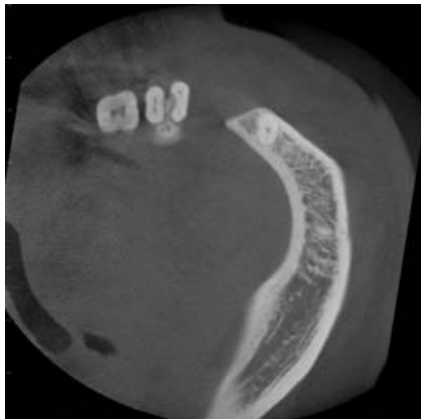


Figure 2C: Axial CBCT image

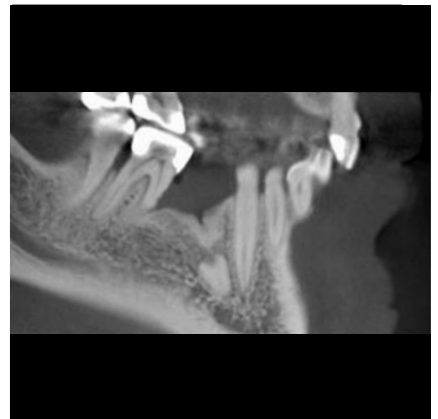


Figure 2D: Sagittal CBCT image

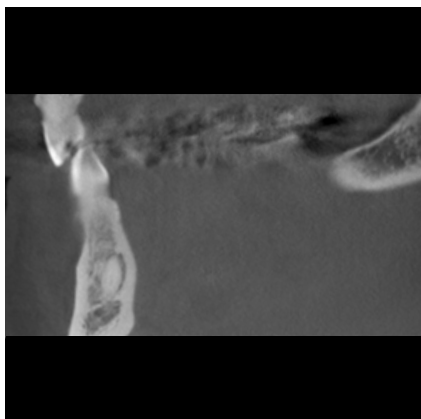


Figure 2E: Coronal CBCT image

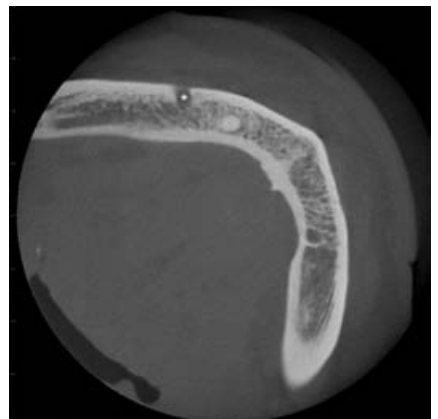


Figure 2F: Axial CBCT image with mental foramen (\*)

# CBCT Imaging for Implant Treatment Planning in the Anterior Mandible

## Relevant clinical questions

Is correct 3-dimensional (3D) implant positioning possible? This includes the number and dimensions (length and diameter) of the implants to be inserted?

Can we achieve good primary stability of the implant in the desired position? If primary stability of the implant is not achievable, the clinician has to decide between site development using guided bone regeneration (GBR) or an alternative treatment concept without dental implants.

When GBR is needed, can we use a simultaneous approach with implant insertion or do we need a staged procedure?

When GBR is not indicated, can we place the implant using a flapless approach?

## Anatomic structures of interest

Apart from the mental nerve, the incisive nerve is the second terminal branch of the inferior alveolar nerve, which has an intraosseous course in a so-called mandibular incisive canal (Figure 1).<sup>1</sup>

This canal is located anteriorly to the mental foramen from both left and right sides of the mandible. Sensory disturbances, caused by direct trauma to the mandibular incisive canal bundle have been reported after implant placement in the interforaminal region.<sup>2</sup>

Besides neurosensory complications, the literature describes several cases with hemorrhage and potentially life-threatening upper airway obstruction in the floor of the mouth following implant placement.<sup>3</sup> Those hemorrhages were mostly related to lingual perforations, long implants or deep osteotomy preparations.

Anatomical structures and characteristics of the posterior mandible that need to be considered, when planning dental implant insertion are:

Lingual foramen (Figure 2)<sup>4</sup>

Incisive canal

Genial tubercles

1. Mardinger O, Chaushu G, Arensburg B, Taicher S, Kaffe I: Anatomic and radiologic course of the mandibular incisive canal. *Surg Radiol Anat* 2000;22:157-61.

2. Jacobs R, Lambrichts I, Liang X, Martens W, Mraiwa N, Adriaenssens P, Gelan J: Neurovascularization of the anterior jaw bones revisited using high-resolution magnetic resonance imaging. *Oral Surg Oral Med Oral Pathol Oral Radiol Endod* 2007;103:683-93.

3. Mardinger O, Manor Y, Mijiritsky E, Hirshberg A: Lingual perimandibular vessels associated with life-threatening bleeding: an anatomic study. *Int J Oral Maxillofac Implants* 2007;22:127-31.

4. von Arx T, Matter D, Buser D, Bornstein MM: Evaluation of location and dimensions of lingual foramina using limited cone-beam computed tomography. *J Oral Maxillofac Surg* 2011;69:2777-85.



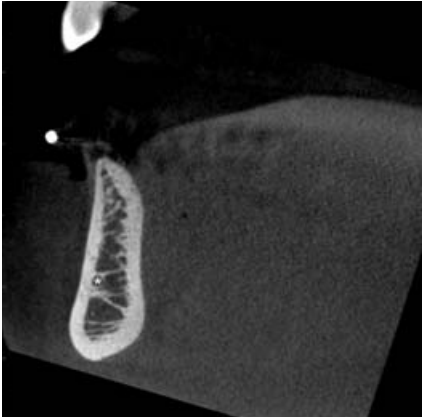


Figure 1A: Coronal CBCT slice

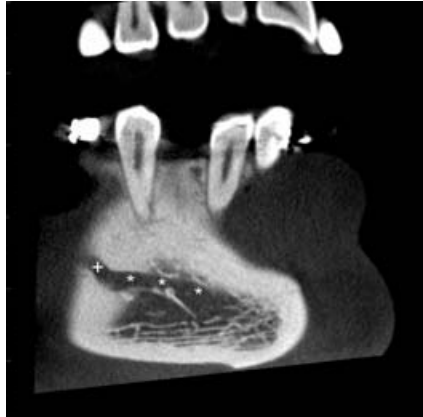


Figure 1B: Sagittal CBCT slice

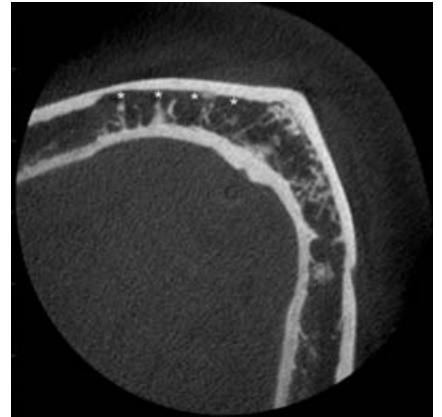


Figure 1C: Axial CBCT slice

Figure 1: Visualization of the course of the incisive canal (\*) in a patient referred for dental implant treatment planning in the right anterior mandible (first premolar region). The mental foramen (+) can be seen disto-apically to the second premolar.

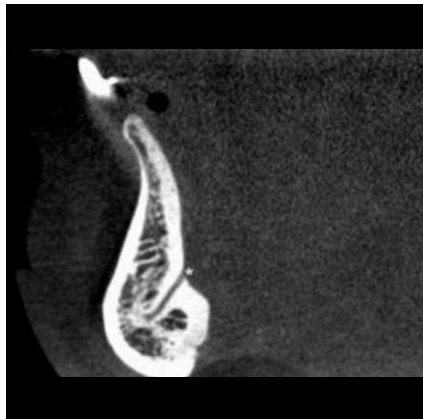

Figure 2A: Sagittal CBCT image

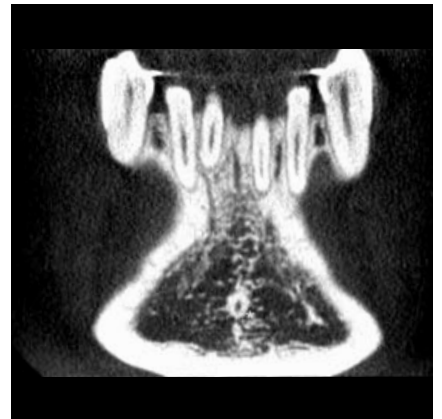


Figure 2B: Coronal CBCT image

Figure 2: Lingual foramen in the region of the symphysis (\*) that enters the mandibular body to form a bony channel.

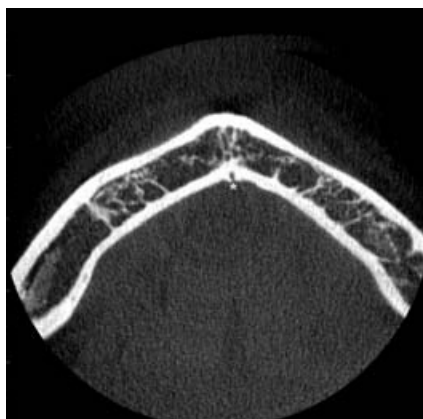

Figure 2C: Axial CBCT image

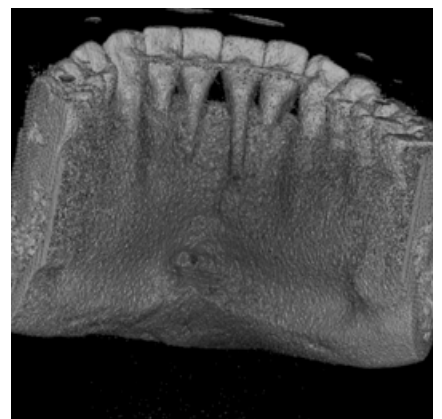


Figure 2D: Volume rendered data set

# Case Example

Replacement of missing mandibular incisors following bone loss due to periodontal disease

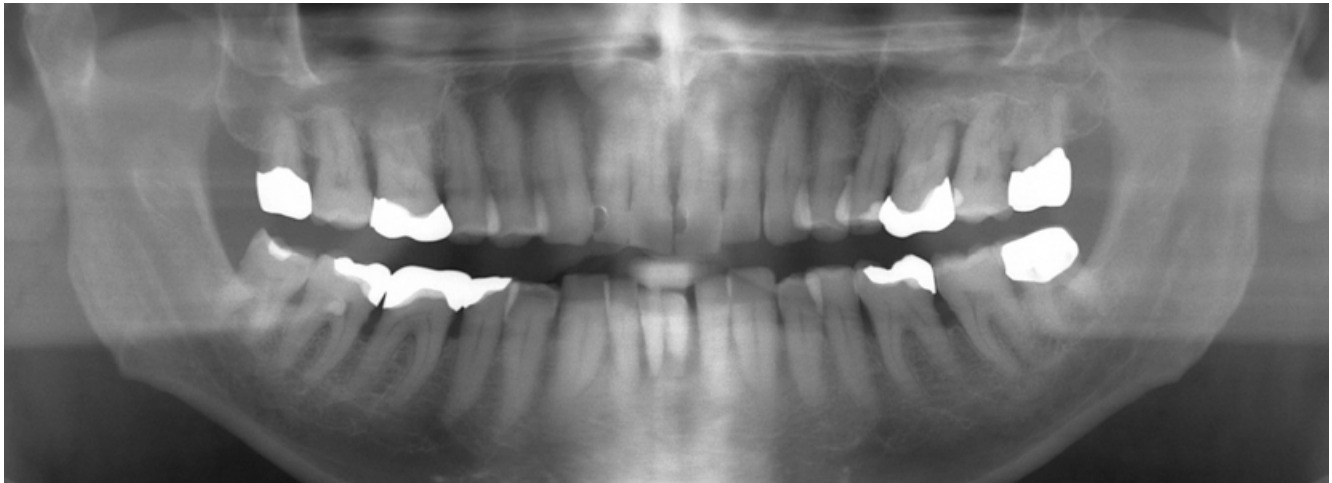


Figure 1: Panoramic view of a 64-year old patient exhibiting generalized bone loss due to periodontal disease including vertical defects in the left maxillary first molar and mandibular incisor area. The patient complained about mobile teeth in the anterior mandible and halitosis.

Figure 2: CBCT analysis and implant treatment planning in the anterior mandibular region following periodontal therapy including extraction of the left maxillary first molar and three mandibular incisors. The 3D images (small FOV: 6 x 6 cm) exhibit sufficient vertical and horizontal bone height for the placement of two dental implants with reduced diameter.

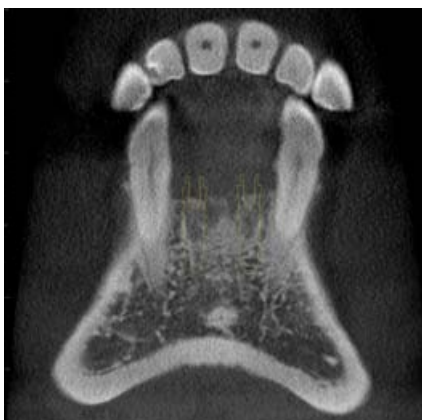


Figure 2A: Coronal CBCT image with both canines laterally to the planned implants

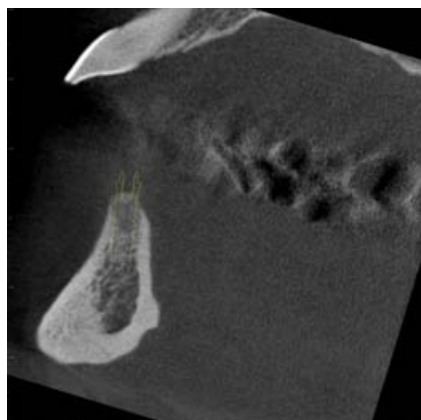


Figure 2B: Sagittal CBCT image for implants in the position of the right and left lateral incisor

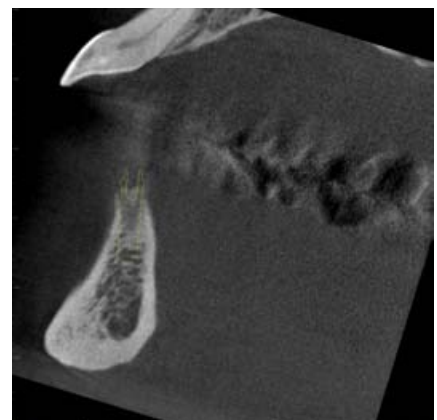


Figure 2C: Sagittal CBCT image for implants in the position of the right lateral incisor

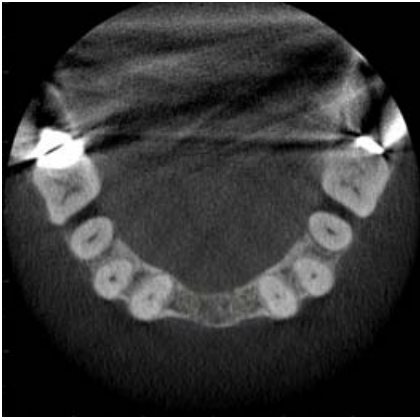

Figure 2D: Axial CBCT image at a coronal and apical position

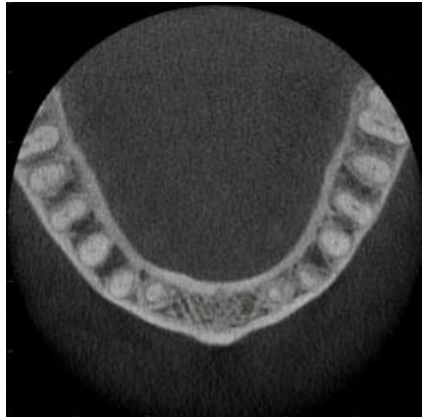


Figure 2E: Axial CBCT image at a coronal position

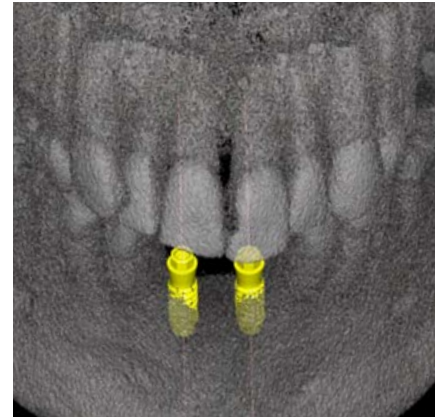

Figure 2F: Volume rendered data set

Figure 3: Presentation two years after dental implant insertion in the region of the anterior mandible. The missing teeth were restored with a fixed partial denture of three units including pink porcelain to cover the bone and soft tissue loss due to initial periodontal breakdown.

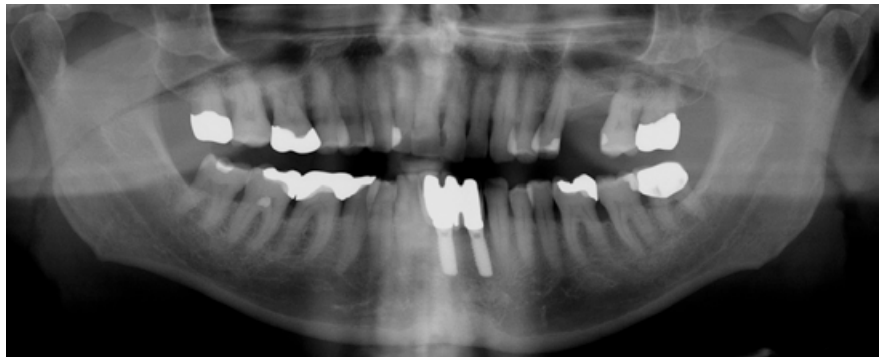


Figure 3A: Panoramic view

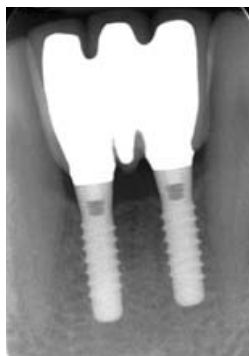

Figure 3B: Periapical radiograph

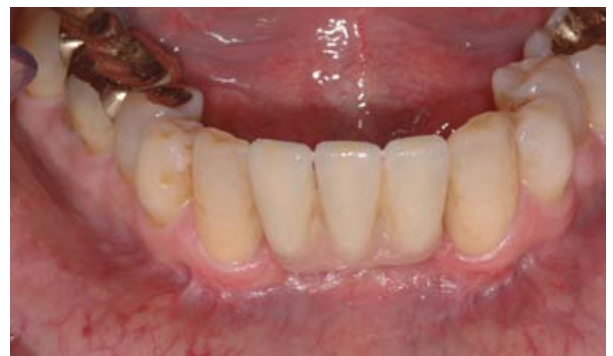

Figure 3C: Clinical aspect

# Examination of Implant Failures and Complications Using CBCT

During the surgical procedure conventional (2-dimensional, extra- and intraoral) radiographic techniques are adequate to confirm the position of an implant in relation to anatomical boundaries. In the absence of symptoms, there is no indication for 3-dimensional radiographic imaging during follow-up. However, CBCT may be helpful for the diagnosis and management of certain post-operative complications.<sup>1</sup>

Implant failures and complications are often caused by implant malpositions in oro-facial direction, which can result in a missing facial bone wall and a compromised esthetic outcome due to mucosal recession (Figures 1 and 2).

When studying claims for neurosensory disturbances of the inferior alveolar nerve, implant placement accounts for only 3% of all reported cases, while being responsible for 12% of all permanent injuries. The latter implies that a high number of neurosensory disturbances following implant placement are found to be of permanent nature (Figure 3).<sup>2</sup>

Postoperative complications after SFE are less common and consist mostly of acute or chronic sinus infection, bleeding, wound dehiscence, exposure of the barrier membrane, and graft loss. Displacement of dental implants can occur during as well as after SFE procedures (Figure 4). In the literature, several case reports have been published with displaced implants into the maxillary sinus. Infections of the maxillary sinus can also be caused by dental implants perforating into the maxillary sinus (Figure 5).

Therefore, indications for CBCT imaging when assessing complications during / after dental implant treatment comprise:

Assessment of malpositioned implants (Figures 1 and 2): Analyze the buccal / oral bone dimensions, and proximity to neighboring roots.

Neurovascular disturbances following most often damage to the mandibular canal (Figure 3), but also can result from damage to the nasopalatine canal, or perforation of the lingual bone plate in the anterior mandible and resulting severe hemorrhages and life-threatening airway obstructions.

Displacement of dental implants into the maxillary sinus (Figure 4), maxillary sinus infection following sinus floor elevation procedures with or without simultaneous dental implant placement (Figure 5) or perforation of the floor of the nose during implant bed preparation and/or placement.

The 3D imaging with CBCT demonstrates in the sagittal slice a deep peri-implant bone loss on the mesial and distal aspect of the implant, which is in agreement with a recurrent peri-implant infection (Figure 1B). The axial slice shows the implant in a facial malposition (Figure 1C). In addition, the implant perforates into the nasopalatal canal (\*). The sagittal slice demonstrates that the implant is not osseointegrated at all on the facial and palatal aspect (Figure 1D).

1. Harris D, Horner K, Gröndahl K, Jacobs R, Helmrot E, Benic GI, Bornstein MM, Dawood A, Quirynen M: Guidelines for the use of diagnostic imaging in implant dentistry 2011: update of the E.A.O. A consensus workshop organized by the European Association for Osseointegration in the Medical University of Warsaw, Poland. Clin Oral Implants Res 2012;23:1243-53.

2. Jacobs R, Quirynen M, Bornstein MM: Neurovascular disturbances after implant surgery. Periodontol 2000 2014 (in press).

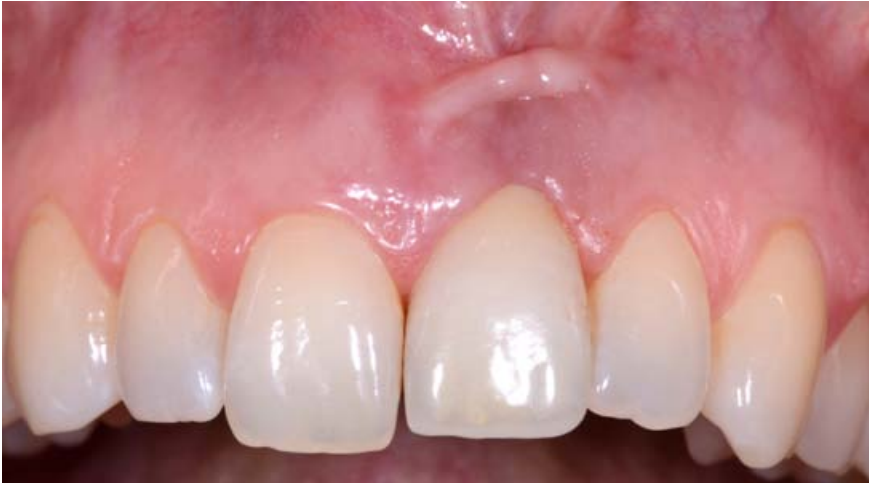

Figure 1A: Clinical aspect at the initial examination

Figure 1: Female patient referred for 3-dimensional analysis of an esthetic complication in the left maxillary incisor region (Figure A). The clinical status exhibits a mucosal recession as well as a flattening and discoloration of the facial mucosa at the implant crown. The patient complained about recurrent peri-implant infections.

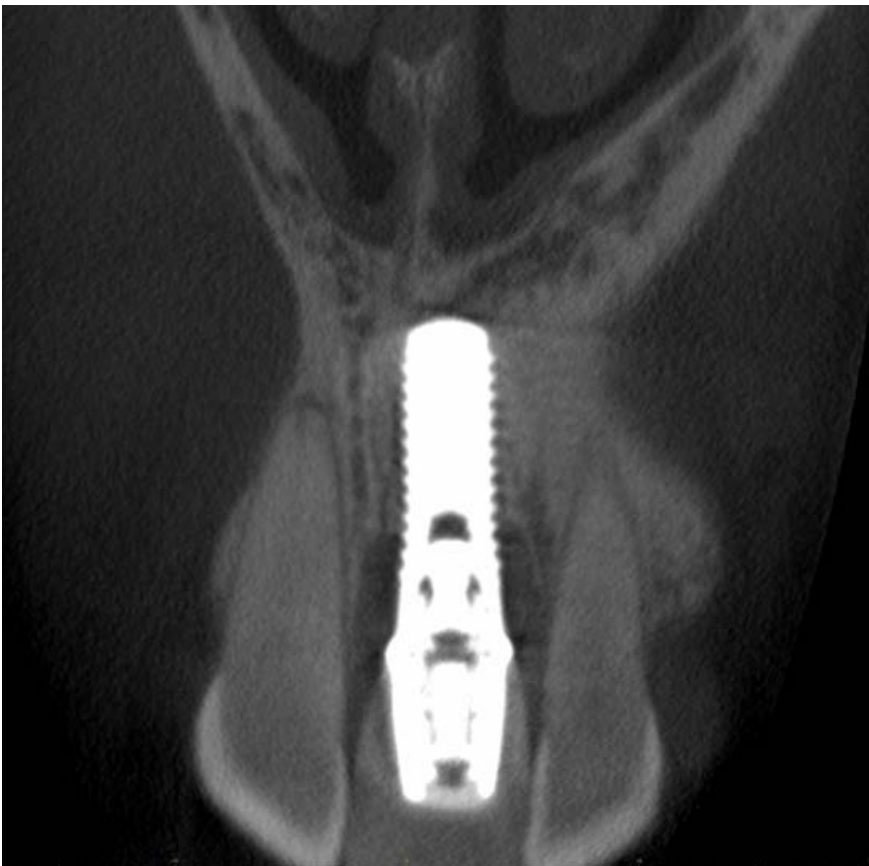

Figure 1B: Sagittal CBCT slice

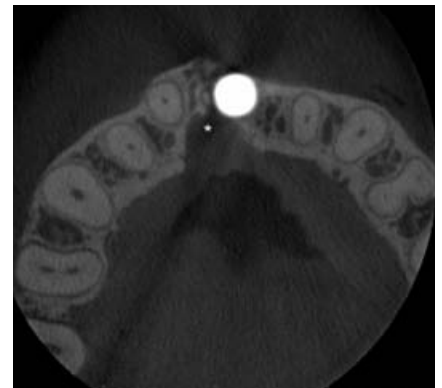

Figure 1C: Axial CBCT slice

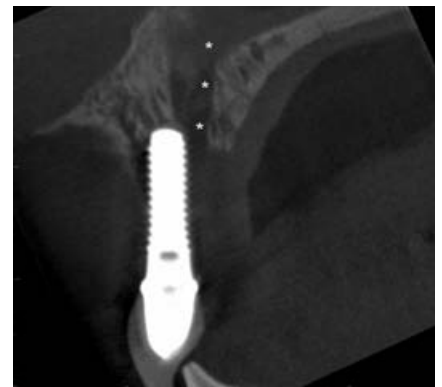

Figure 1D: Sagittal CBCT slice

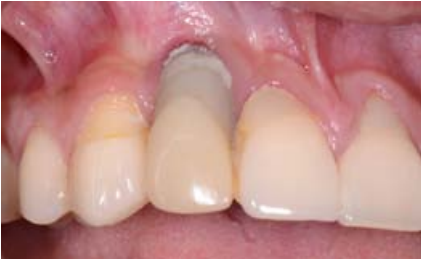

Figure 2A: Clinical aspect

Figure 2: 30-year old male patient referred for 3-dimensional analysis and treatment of an esthetic implant failure in the right lateral maxillary incisor region. The clinical status exhibits a severe mucosal recession and plaque accumulation (Figure 2A). The respective CBCT images confirm that the implant has been inserted in an incorrect axis (Figures 2B to 2E) and that the inserted implant is too large or oversized, since it almost touches the adjacent teeth (Figures 2C to 2E).

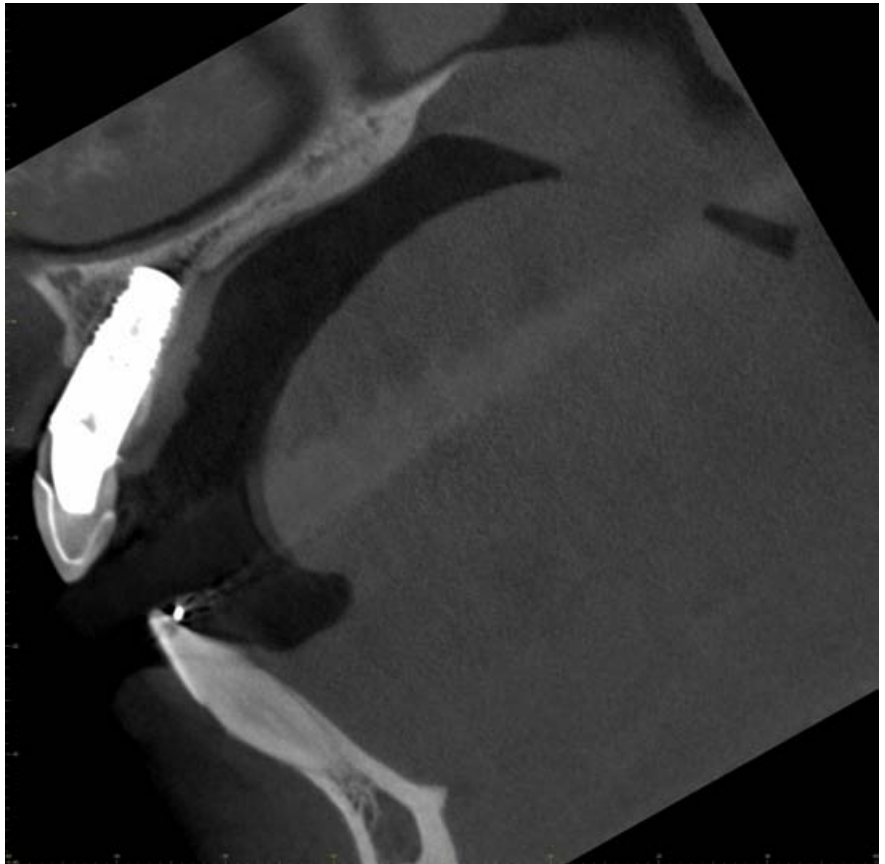


Figure 2B: Sagittal CBCT slice

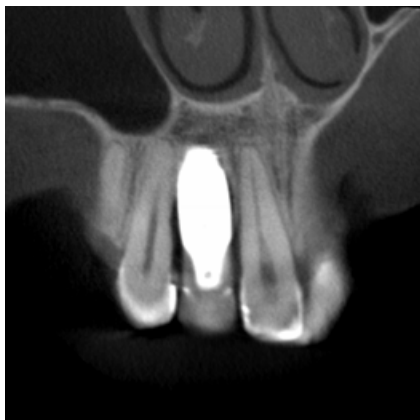


Figure 2C: Coronal CBCT slice

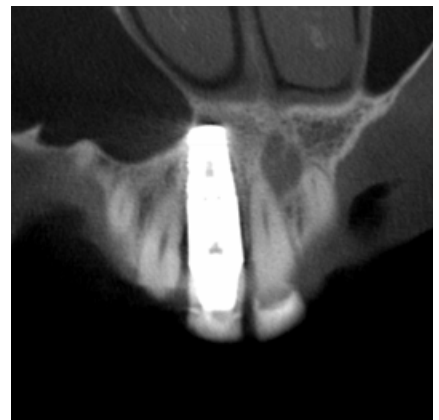

Figure 2D: Coronal CBCT slice

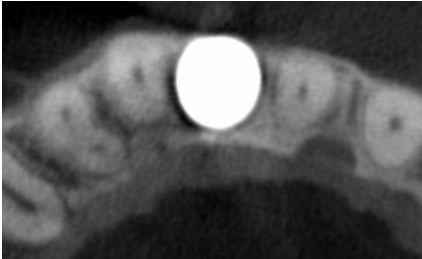


Figure 2E: The axial CBCT slice confirms the oversized diameter of the implant filling almost the entire edentulous space

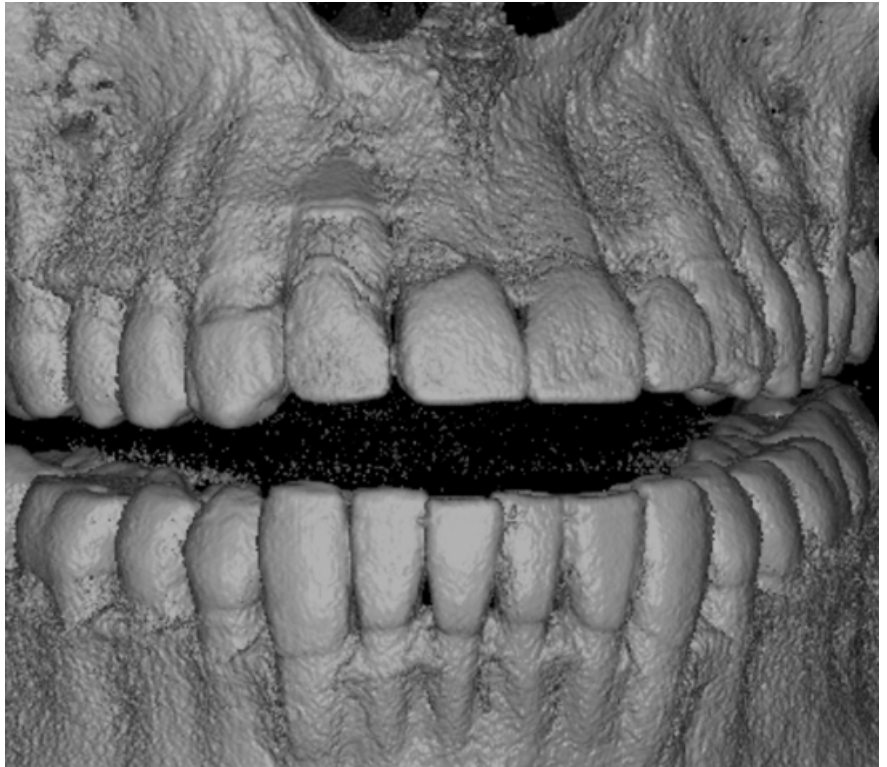


Figure 2F: Volume rendered data set

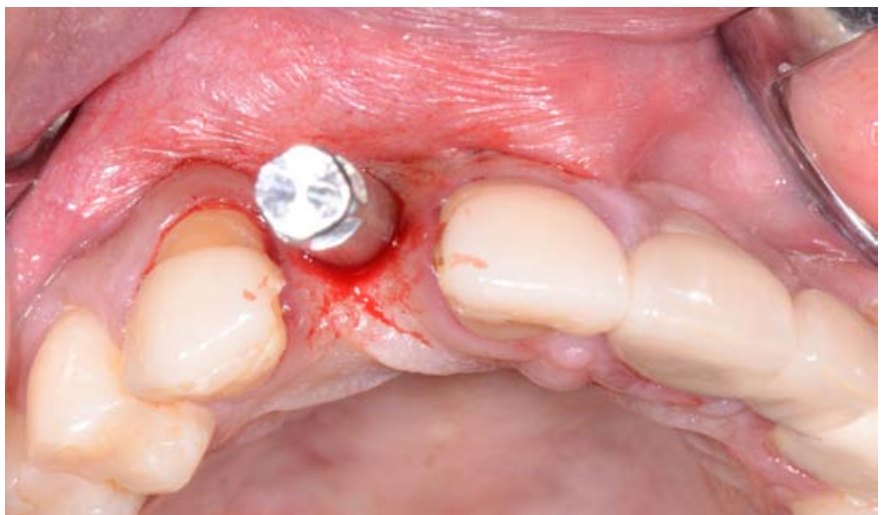

Figure 2G: Upon removal of the implant, the extreme buccal angulation of the dental implant becomes visible

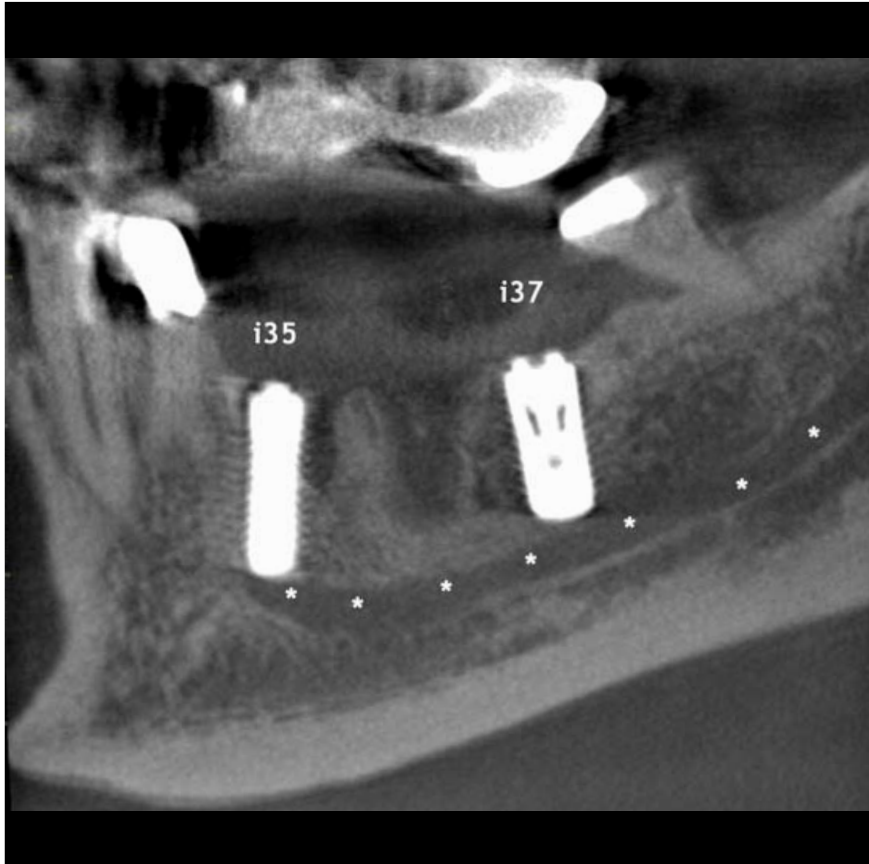


Figure 3: Patient referred for evaluation neurosensory disturbances in the region of the mental nerve following implant placement in the second premolar (i35) and second molar (i37) region of the left posterior mandible. The CBCT images show that i35 is inserted partially into the mandibular canal and mental foramen region.  
\* = mandibular canal / mental foramen.

Figure 3A: Sagittal CBCT image

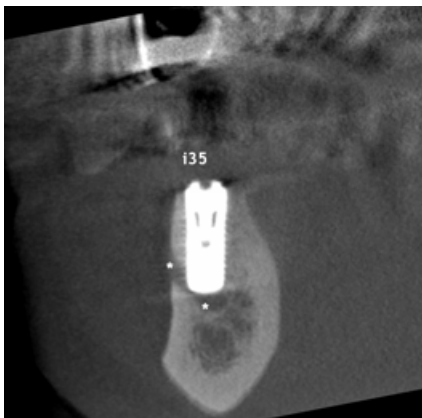


Figure 3B: Coronal CBCT image

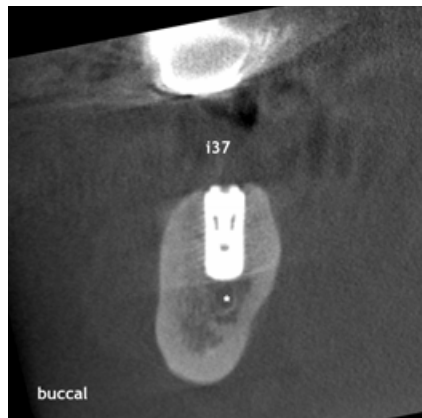


Figure 3C: Coronal CBCT image

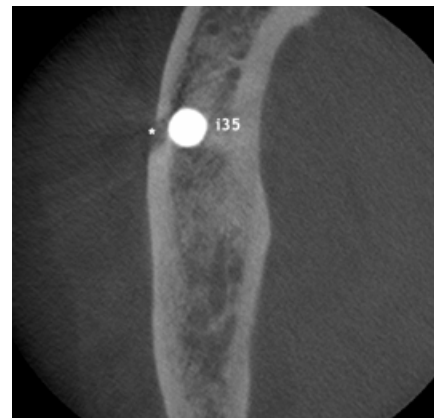


Figure 3D: Axial CBCT image



Figure 4: Patient referred for evaluation of the whereabouts of the implant inserted at the position of the left maxillary first molar. The CBCT images show that the implant has been displaced into the maxillary sinus, and that the Schneiderian membrane exhibits an inflammatory reaction with air-bubbles (sign for an acute sinusitis).

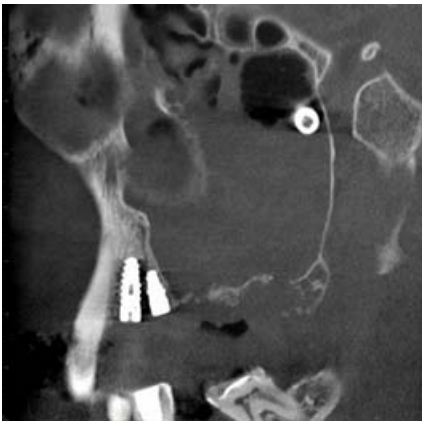


Figure 4A: Sagittal CBCT image

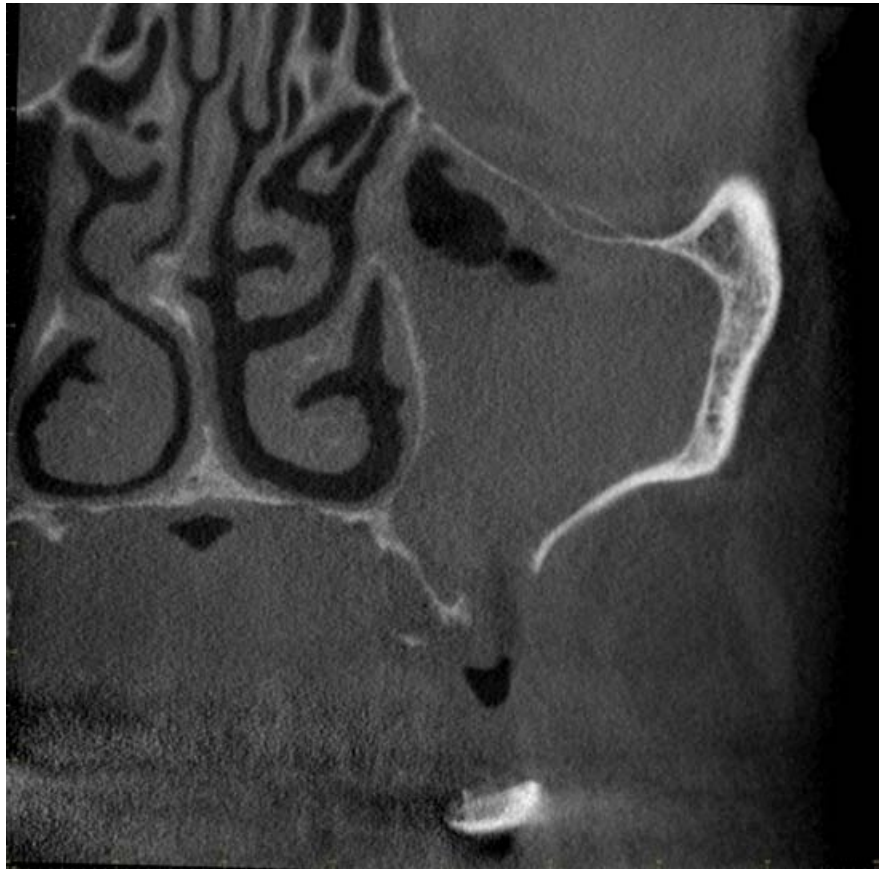

Figure 4B: Coronal CBCT image at the region of the first molar with visible perforation of the cortical bone of the maxillary sinus

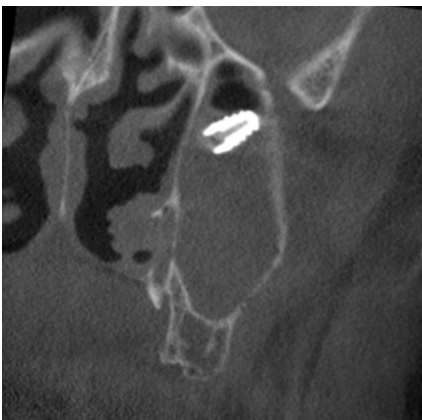


Figure 4C: Coronal CBCT image at the distal aspect of the maxillary sinus

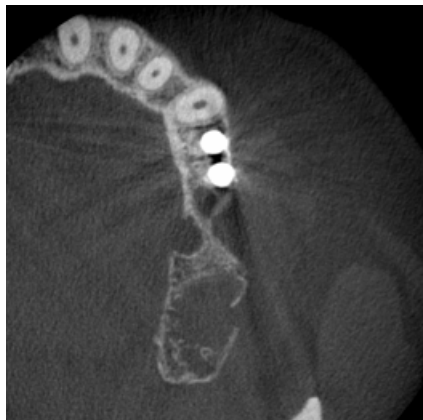

Figure 4D: Axial CBCT image

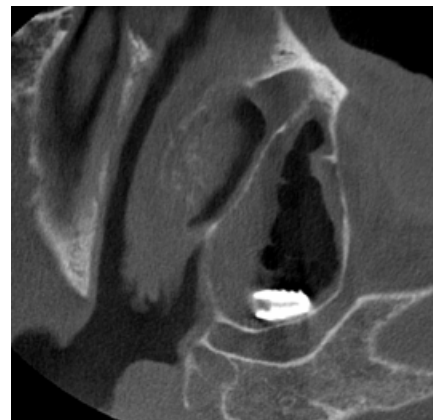


Figure 4E: Axial CBCT image

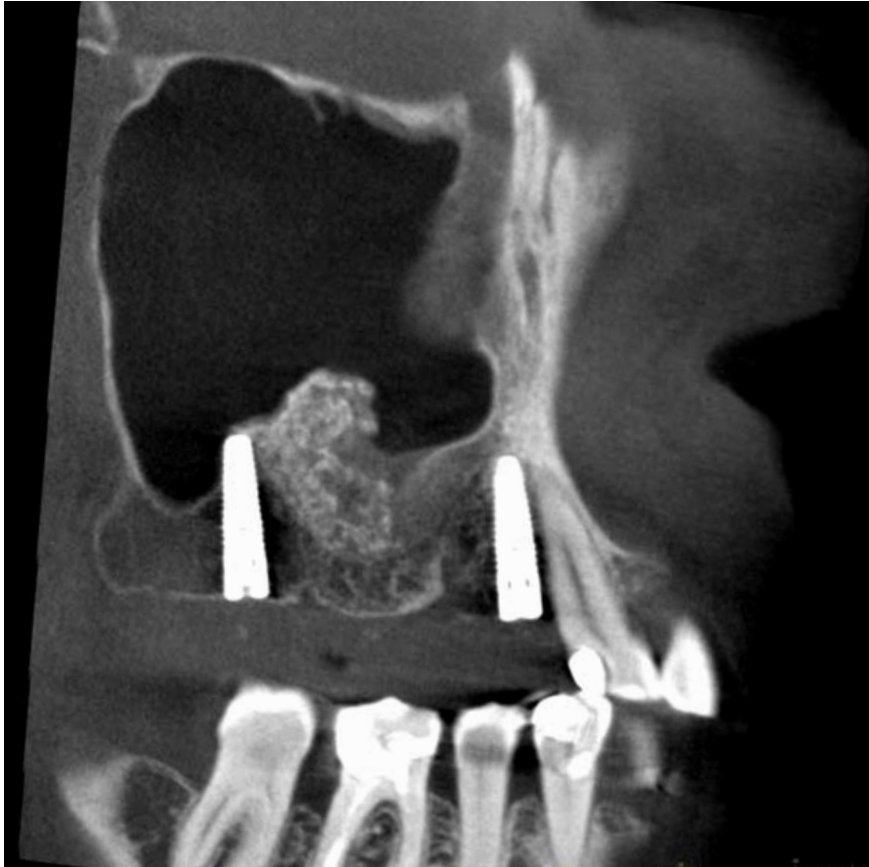

Figure 5A: Sagittal CBCT image of the right maxillary sinus

Figure 5: A 57-year old male patient was referred for evaluation of acute sinusitis symptoms on the left side following implant placement and sinus floor elevation (SFE). The CBCT images (medium FOV: 8 x 8 cm) show that two dental implants (first premolar, second molar) and a SFE procedure had been performed on the right side. On the left, two dental implants are visible in the first premolar and second molar position. The maxillary sinus on the right (Figure 5A) is pneumatized without signs of pathology, whereas the left sinus is opacified and the basal lateral bone wall in the region of the second molar is missing – probably the entry site for the SFE. In the sinus, some foreign body material can be diagnosed, which is most likely grafting material from the failed SFE procedure. The distal implant perforates into the maxillary sinus (Figure 5B). The diagnosis was a maxillary sinusitis of odontogenic (iatrogenic) origin. Based on these findings, the patient was referred to the ear, nose, throat (ENT) specialist for treatment.

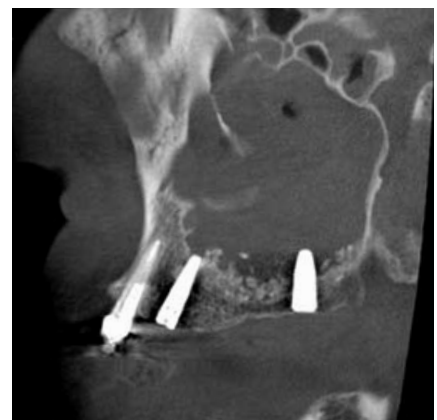

Figure 5B: Sagittal CBCT image of the left maxillary sinus

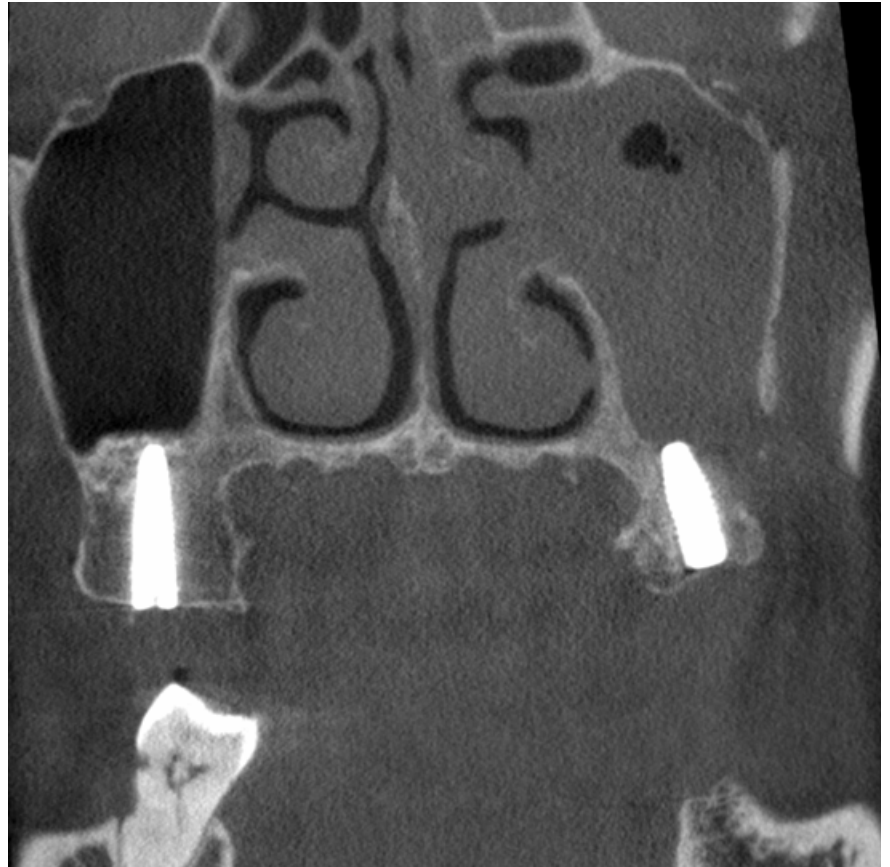


Figure 5C: Coronal CBCT image, second molar implant regions on both sides

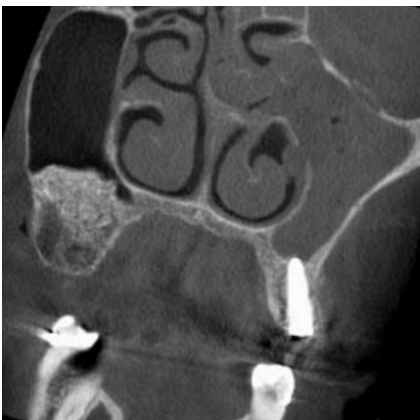

Figure 5D: Coronal CBCT image, first molar region on the right, first premolar implant region on the left

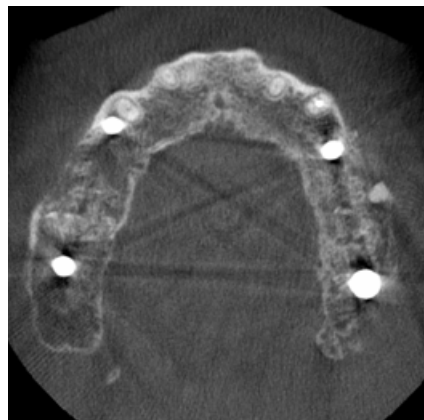


Figure 5E: Axial CBCT image



Development and Manufacturing

**J. MORITA MFG. CORP**

680 Higashihama Minami-cho. Fushimi-ku,  
Kyoto-shi, Kyoto 612-8533. Japan  
T +81. (0)75. 611 2141, F +81. (0)75. 622 4595  
[www.jmorita-mfg.com](http://www.jmorita-mfg.com)

**Morita Global Website**  
[www.morita.com](http://www.morita.com)

Distribution

**J. Morita Corporation**

3-33-18 Tarumi-cho. Suita-shi, Osaka 564-8650. Japan  
T +81. (0)6. 6380 1521, F +81. (0)6. 6380 0585

**J. Morita USA, Inc.**

9 Mason. Irvine CA 92618. USA  
T +1. 949. 581 9600, F +1. 949. 581 8811

**J. Morita Europe GmbH**

Justus-von-Liebig-Strasse 27a. 63128 Dietzenbach. Germany  
T +49. (0)6074. 836 0, F +49. (0)6074. 836 299

**J. Morita Corporation Australia & New Zealand**

Suite 2.05, 247 Coward Street. Mascot NSW 2020. Australia  
T +61. (0)2. 9667 3555, F +61. (0)2. 9667 3577

**J. Morita Middle East**

4 Tag Al Roasaa, Apartment 902. Saba Pacha 21311 Alexandria.  
Egypt T +20. (0)3. 58 222 94, F +20. (0)3. 58 222 96

**Siamdent Co., Ltd.**

444 Olympia Thai Tower, 3rd Floor, Ratchadapisek Road. Samsennok,  
Huay Kwang, Bangkok 10310. Thailand  
T +66. (0)2. 512 6049, F +66. (0)2. 512 6099  
[www.siamdent.com](http://www.siamdent.com)

Catalog Design: f/p design, Germany

Subject to technical changes and errors.  
12.16 Implant Dentistry

Diagnostic and Imaging Equipment

Treatment Units

Handpieces and Instruments

Endodontic System

Laser Equipment

Laboratory Devices

Educational and Training Systems

Auxiliaries